

Kertas Asli/Original Articles

**Custom Made Ocular Prosthesis at Optometry Clinic Universiti Kebangsaan
Malaysia (UKM)**
(Prostesis Okular Buatan Khas di Klinik Optometri, Universiti Kebangsaan Malaysia (UKM))

NORHANI MOHIDIN, CHIA JHO YAN, MOHD NORHAFIZUN MOHD SAMAN & NAZEEM DESAI

ABSTRACT

Patients who lost their eyes as results of accidents or diseases (e.g. retinoblastoma) usually underwent enucleation or evisceration. They were then fitted with ocular prosthesis to prevent collapse of the globe and also for cosmetic effects. Custom made ocular prosthesis is almost unheard of in this country for most hospitals supply ready-made (stock) prosthesis. The cosmetic results of stock prosthesis are often unsatisfactory. Besides being uncomfortable, stock prosthesis may also induce allergic reaction that may lead to papillary conjunctivitis. The Optometry Clinic at UKM started its custom made prosthetic service in 2010. We described here two cases of patients who complained of discomfort with their old stock prosthesis and re-fitted with custom made prosthesis. We also highlight the importance of proper hygiene and maintenance so that ocular prosthesis can be used for as long as possible. This article aims to create awareness among eye care practitioners and showcase the cosmetic benefits of custom made ocular prosthesis.

Keywords: Custom made ocular prosthesis, Ocular prosthetics, Artificial eye

ABSTRAK

Pembuatan prostesis okular khas hampir tidak pernah didengar di negara ini kerana kebanyakan hospital membekalkan prostesis sedia-siap (stok prostesis). Hasil kosmetik prostesis sedia-siap selalunya tidak memuaskan. Selain daripada tidak selesa, prostesis sedia-siap juga boleh menyebabkan reaksi alahan yang menjurus kepada konjunktivitis papilari. Klinik Optometri di UKM memulakan perkhidmatan prostesis buatan khas pada tahun 2010. Kami tonjolkan di sini dua kes pesakit yang memakai prostesis sedia-siap, mengadu akan tidakselesannya dan di pasang semula dengan prostesis yang direka bentuk khas untuk mata mereka. Kami tekankan juga aspek kebersihan dan penyelenggaraan supaya prostesis okular boleh digunakan untuk masa yang lama. Artikel ini bertujuan untuk menghasilkan kesedaran dalam kalangan pengamal kesihatan mata dan menunjukkan kebaikan kosmetik prostesis yang direka bentuk khas.

Kata kunci: Prostesis okular direka bentuk khas, Mata batu, Mata palsu

INTRODUCTION

Anophthalmic individuals who had their eye enucleated or eviscerated need ocular prosthesis fitted to the socket of the eye to appear normal. Ocular prosthesis is usually fitted by ocularists (skilled individuals involved in fabricating ocular prosthesis) and optometrists who have acquired the necessary skills and experience. It is a novel practice that requires time, patience and dedication. Anophthalmia refers to absence of the eye as a result of enucleation or evisceration of the globe (Kaiser & Friedman 2009). Enucleation involves removing both the globe and a segment of the anterior optic nerve while preserving the conjunctiva, Tenon's capsule, and the extraocular muscle. Evisceration involves removing the ocular contents but preserving the sclera and sometimes, the cornea (Morton 2003). It is important for anophthalmic patients to have prosthesis to prevent the collapse of orbital bony structure which leads to facial asymmetry that may be socially unacceptable (Raizada & Rani 2007).

Ocular prosthesis can be either ready-made (stock) or custom made. If a stock prosthesis is used, the fit of the prosthesis to the tissue bed may not be optimum and thus leads to less than ideal support for the orbit and eyelids. Usually, stock prosthesis needs re-polishing so that its fit on the enucleated or eviscerated eye is optimized.

Custom made prosthesis involve taking an impression of the enucleated eye, making and designing the prosthesis so that it closely resemble the other eye, mainly for cosmetic effect. Besides that, the close adherence of custom made ocular prosthesis to the tissue bed provides maximum comfort and restores full physiologic function to the accessory organs of the eye. With close adherence, voids that collect mucus and debris that can be a source of irritation to the mucosa and a potential source of infection to the eye are minimized. Custom made prosthesis also provides optimum cosmetic and functional results (Cain 1982). The eyes appear more symmetrical but custom made prostheses are tedious to make and it needs skill and experience to produce satisfactory results.

In Malaysia, it is difficult to find ocularists or optometrists that make prosthesis. In government hospitals prosthesis are usually imported, kept as stock lenses and dispensed to patients when necessary. Relatively it is cheaper to make custom made prosthesis rather relying on imported products from overseas. There is also a chance that stock prosthesis do not fit on the eye as well as custom made prosthesis. We described here two cases of adult patients who had undergone enucleation and evisceration, fitted with stock prosthesis and recently refitted with custom made prosthesis to show the differences. These cases highlight the need for ophthalmic services which have been neglected in our country.

CASE REPORTS

FIRST CASE

A 51-year old Malay man was referred to the UKM Optometry Clinic for a re-fitting of his left ocular prosthesis. He complained that his ocular prosthesis was small for his current socket as he has been wearing the same prosthesis for more than 20 years. Observation of his left ocular prosthesis at primary position revealed a smaller eye with ptosis (Figure 1a). He lost his eye as a child in 1970 due to a trauma involving a firecracker explosion. His eye was enucleated after that incident. He was fitted with a stock ocular prosthesis shortly after enucleation in the same year and had only changed his prosthesis twice since then. He had difficulty finding a practitioner that offered prosthesis service. Due to the same reason, he has not sent his current prosthesis for polishing for more than 20 years. The patient was refitted with a custom made prosthesis.

A follow up assessment showed that the patient adapted well and had no problems with his new ocular prosthesis as the size and fit was custom made to his socket (Figure 1b). He cleaned his prosthesis once in one or two

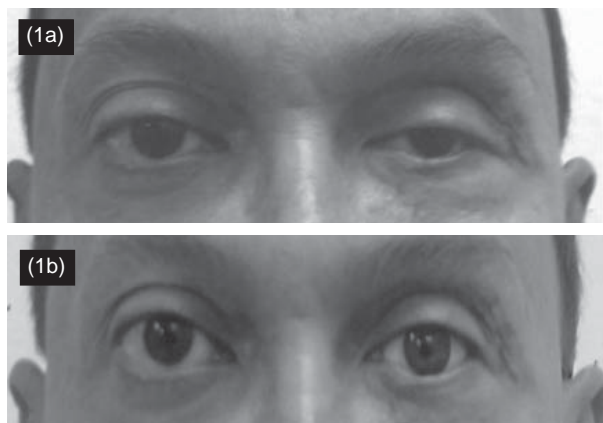


FIGURE 1. Appearance of Case 1 patient with stock prosthesis (1a - Left eye) and newly fitted custom made prosthesis (1b - Left eye). The stock prosthesis was small for patient who appeared like having ptosis. His new custom made prosthesis gives better aesthetic effect

weeks and seldom removed them. He used topical ocular lubricants to relieve any discomfort whilst wearing and used rigid gas permeable lens cleaner for disinfecting and saline for rinsing.

SECOND CASE

A 55-year old Malay lady fitted with a stock ocular prosthesis from a rural hospital in 2007 was also referred for a re-fitting of her right ocular prosthesis. She complained of discomfort with her current ocular prosthesis. Observation with the slit lamp biomicroscopy revealed significant amount of mucoid discharge, swollen lids and hyperemic palpebral conjunctiva. Entropion was noted on the upper and lower lid with madarosis at the nasal portion of her lower eyelid. It was seen that her ocular prosthesis was ill-fitted and appeared bigger than required (Figure 2a). The patient had undergone evisceration to remove her right non-functional eye due to complications from advanced diabetic eye disease. She was refitted with a custom made ocular prosthesis.

A follow up assessment showed the patient was much happier with the appearance of her new custom made prosthesis (Figure 2b). She also felt her new prosthesis was more comfortable compared to her previous one. She rinsed her prosthesis daily with saline before wearing in the morning and used a rigid gas permeable cleaner for cleaning every three days. She also used lubricating drops before inserting her ocular prosthesis into its socket. This patient also complained of occasional discharge and sending the prosthesis for polishing did not eliminate this problem. The patient was referred back to the ophthalmologist to alleviate this problem.

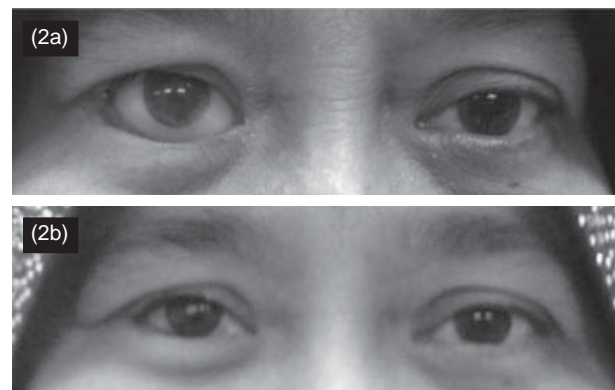


FIGURE 2. Appearance of the Case 2 patient with stock (2a - Right eye) and new custom made ocular prosthesis (2b - Right eye). With custom made prosthesis both eyes appear equal in size

DISCUSSION

We reported two cases involving patients who were not satisfied with their existing ocular prosthesis, prescribed from stock lenses in government hospitals some 20 and

5 years ago. However since prosthesis service is sparse patients made do with whatever is available to them. Song et al. (2006) found about 72% of anophthalmic patients were satisfied with their ocular prosthesis. However recent studies by Ahn et al. (2010) in Korea and Rasmussen (2010) in Denmark found a lower quality of life among anophthalmic patients compared to their normal counterpart. Although we did not carry out any psychological assessment on our two patients they seemed happy enough possibly because of their acceptance and it had been a long time since they lost their eyes.

Studies had indicated that enucleated sockets experience growth retardation and facial asymmetry especially in children undergoing enucleation without orbital replacement therapy. These children experience bony orbital collapse and impairment (Yago & Furuta 2001; Christmas et al. 2000). It is therefore important for prosthesis to be implanted soon after enucleation or evisceration. In Case 1, the patient met with fire cracker accident when he was very young but fortunately he was fitted soon after surgery, therefore he did not suffer consequences of enucleation such as orbital collapse. Unfortunately both patients were fitted with stock prosthesis that did not really fit well. It has been shown that stock prosthesis results in poor apposition between it and the surface that leads to uneven weight distribution and constant irritation that eventually present as chronic discharge. Patient in Case 2 who complained of discharge possibly suffered from chronic papillary conjunctivitis that occurred as results of constant mechanical irritation between the surrounding ocular tissue and the prosthesis (Raizada & Deepa 2007).

Acrylic prosthesis is usually mechanically resistant and can last between 5–10 years. This was clearly seen in Case 1 where patient wore the same prosthesis for more than 20 years. However, the practice of not sending prosthesis back for periodic polishing is not advised as acrylic prosthesis can attract deposits such as proteins and lipids from tears and these in the long term may cause allergic reaction, as results of mechanical irritation between the prosthesis and surrounding tissues during eye movement or blinking. Prosthesis has to be polished once a year or in some cases every six-month to maintain smooth and clean surface (Somkwar et al. 2009; Nagaral & Moldi 2011).

Prosthesis needs to be periodically cleaned with disinfectant. Generally, cleaning with mild antibacterial soap, multipurpose contact lens solution and chlorhexidine disinfectant has been found effective (Paranhos et al. 2007). Abrasive disinfectant usage is discouraged as the acrylic material has been found to have physical property changes with disinfectant, which may decrease its durability (Moreno et al. 2012).

Cleaning frequency has been reported to vary from once every 24 hours to once a week. Daily cleaning as practiced by patient in Case 2 is not recommended (Osborn and Hetler 2010), because frequent removal may irritate the socket which in turn can cause allergic reaction. Allergic

reaction can result in mucus discharge and discomfort to the patient (Hegde et al. 2011; Kalavathi et al. 2010; Somkuwar et al. 2009; Rasmussen 2010). Patient in Case 2 practiced daily removal of ocular prosthesis upon awakening in the morning. To overcome this discomfort ocular lubricant is recommended. Both our patients used ocular lubricants for comfort and a RGP lens cleaner for cleaning their prostheses. Mucus discharge as experienced by patient in Case 2 was probably due to allergic conjunctivitis. This is one of the possible side effects as results of wearing prosthesis and can be caused by inadequate instillation, improper cleaning and disinfection, accumulation of secretions over many years that may cause papillary conjunctivitis and eventually lead to intolerance to prosthesis (Swann & Schmid 2001). In this case the patient was referred back to the ophthalmologist for treatment.

Patient in Case 2 experienced discharge with poorly fitted prosthesis which reduced after re-fitting with custom made prosthesis. Poorly fitting ocular prosthesis surface can lead to the rare conjunctival squamous cell carcinoma (Jain et al. 2010) and ligneous conjunctivitis (Yazici et al. 2011). Hence, a good fitting ocular prosthesis with proper hygiene contributes significantly to its long term wearing success.

In both of the above cases, the Direct Impression technique as suggested by Barlett & Moore (1973) was used. Both patients were instructed to disinfect the prosthesis with rigid gas permeable contact lens cleaner at least once a week and rinse with saline solution. They were briefed on the procedures of prosthesis insertion and removal. They were also warned not to use abrasive solutions to clean the prosthesis and encouraged to use ample amount of ocular lubricants to improve comfort. Half yearly checkups were advised for screening and alleviating potential problems related to prosthesis wear.

Fitting of ocular prosthesis not only benefits patients in terms of ocular support and facial symmetry, it also restores the anophthalmic patients' social life (Chin et al. 2006). Lukman et al. (2011) showed that a child as young as 5-years old could have impaired social interaction for having abnormal eyes. It is gratifying to note that both our patients appeared not be affected by their abnormalities.

RECOMMENDATION

We highlighted 2 cases of enucleation and evisceration fitted with stock prostheses and showcased the differences in cosmetic appearance when custom made prostheses were fitted on their eyes. Besides being cosmetically acceptable, custom made prosthesis also give greater comfort to patients with fewer side effects in the long term. This is due to the close apposition between prosthesis and the tissues surrounding the eyes that allow for even distribution of volume and weight in the socket. The close proximity between the prosthesis and the surrounding tissues also lessen mechanical irritation to the tissues when the eyes move at different direction of gaze.

We also highlighted the importance of cleaning and maintenance regime so that prosthesis can be made comfortable and be used for as long as possible. Although we realized that prosthesis service is lacking in the country we hope that our paper will create awareness among health care professionals related to eye care on the importance of custom made prosthesis when faced with rehabilitation of patients who have just undergone enucleation or evisceration.

The prompt fitting of an ocular prosthesis after enucleation or evisceration is important as it not only restores a person's facial symmetry but also enables them to return to normal social interaction and normal life. Although the incidence of evisceration and enucleation is relatively small in this country (Tajunisah et al. 2007), the service for rehabilitation of patients with such conditions is important for the well being of a small sector of society.

ACKNOWLEDGEMENT

We would like to thank the Head and Staff of the Optometry & Vision Science Program, Faculty of Health Sciences, UKM for help rendered during the making of the prosthesis. We acknowledge the permission given by our patients to publish their cases.

REFERENCES

- Ahn, J.M., Lee, S.Y. & Yoon, J.S. 2010. Quality of Life in the Emotional Status of Anophthalmic Patients in Korea. *Am. J. of Ophthalmol.* 149(6): 1005-1011.
- Bartlett, S.O. & Moore, D.J. 1973. Ocular prosthesis: a physiologic system. *J. Prosthet. Dent.* 29: 450-459.
- Cain, J.R. 1982. Custom Ocular Prosthesis. *J. Prosthet. Dent.* 48: 690-694.
- Chin, K., Margolin, C. & Finger, P. 2006. Early prosthesis improves quality of life after enucleation. *Optometry* 77: 71-75.
- Christmas, N.J., Van Quill, K., Murray, T.G. et al. 2000. Evaluation of efficacy and complications: primary pediatric orbital implants after enucleation. *Arch. Ophthalmol.* 118: 503-506.
- Hegde, V., Hassija, J., Nayak, R. & Sridhar, N. 2011. Ocular Impression in Children: Review of Literature and a Case Report. *Ind. J. Dent.* 2(4): 175-180.
- Jain, R.K., Mehta, R. & Badve, S. 2010. Conjunctival squamous cell carcinoma due to ocular prostheses: a case report and review of literature. *Pathol. Oncol. Res.* 16(4): 609-612.

Norhani Mohidin
Chia Jho Yan
Mohd Norhafizun Mohd Saman
Optometry and Vision Sciences Program
Faculty of Health Sciences
Universiti Kebangsaan Malaysia
Jalan Raja Muda Abdul Aziz
50300 Kuala Lumpur

- Kaiser, P.K. & Friedman, N.J. 2009. *Essentials of Ophthalmology*. Philadelphia: Elsevier Limited.
- Kalavathi, S., Moldi, A. & Kumar, P. 2010. Restoring ocular esthetic using ocular prosthesis. *J. Dental Sci. & Res.* 1(2): 39-44.
- Lukman, H., Kiat, J.E., Ganesan, A., Chua, W.L., Khor, K.L. & Choong, Y.F. 2010. Strabismus-related prejudice in 5-6 year old children. *Br. J. Ophthalmol.* 94(10): 1348-1351.
- Moreno, A., Goiato, M., Santos, D., Haddad, M., Pesqueira, A. & Bannwart, L. 2012. Effect of different disinfectants on the microhardness and roughness of acrylic resins for ocular prosthesis. *Gerontology*. Accessed May 20, 2012. doi:10.1111/j.1741-2358.2012.
- Morton, A. 2003. Enucleation and Evisceration In *Ophthalmic Care of Combat Casualty*. Washington, DC: Department of the Army, Office of The Surgeon General, and Borden Institute.
- Nagaral, S. & Moldi, A. 2011. Ocular Defect Management by Custom Made Ocular Prosthesis. *Int. J. Dent. Clin.* 3(3): 83-84.
- Osborn, K. & Hettler, D. 2010. A Survey on Recommendations of the Care of Ocular Prostheses. *Optometry* 81: 142-145.
- Paranhos, R., Batalhao, C., Semprini, M., Regalo, S., Ito, I. & Mattos, M. 2007. Evaluation of ocular prosthesis biofilm and anophthalmic cavity contamination after use of three cleansing solution. *J. Appl. Oral Sci.* 15(1): 33-38.
- Rasmussen, M. 2010. The amputated eye: consequence of eye amputation with emphasis on clinical aspects, phantom eye syndrome and quality of life. *Acta Ophthalmol.* 88(2): 1-25.
- Raizada, K. & Rani, D. 2007. Review – Ocular prosthesis. *Contact Lens & Anterior Eye* 30: 152-162.
- Swann, P. & Schmid K. 2001. Giant papillary conjunctivitis associated with ocular prosthesis. *Clin. and Expt. Optom.* 84(5): 293-295.
- Somkuwar, K., Mathai, R. & Jose, P. 2009. Ocular Prosthesis: Patient Rehabilitation – A Case Report. *People's J. of Scient Res.* 2(2): 21-26.
- Song, J.S., Oh, J. & Baek, S.H. 2006. A survey of satisfaction in anophthalmic patients wearing ocular prosthesis. *Graefe's Arch. Clin. & Expt. Ophthalmol.* 244: 330-335.
- Tajunisah, I., Reddy, S.C. & Mas-Ayu, S. 2007. A study of indications and changing trends of enucleation and evisceration in West Malaysia. *Int. J. Ophthalmol.* 7(1): 27-30.
- Yago, K. & Furuta, M. 2001. Orbital growth after unilateral enucleation in infancy without an orbital implant. *Jpn. J. Ophthalmol.* 45: 648-652.
- Yazici, B., Yildiz, M. & Irfan, T. 2011. Induction of bilateral ligneous conjunctivitis with the use of prosthetic eye. *Int Ophthalmol.* 31: 25-28.

Nazeem Desai
Private Practice, Shop5,
Desai's Centre, 92 Main Road De Deur,
South Africa.

Correspondence author: Norhani Mohidin
Email address: nmohidin@medic.ukm.my
Tel: 603-92897687/7499, Fax: 603-26910488

Received: January 2013
Accepted for publication: March 2013