

Editorial

Adult Hirschsprung's Disease: Diagnosis and Dilemmas

Zaidi Z

Department of Surgery, School of Medical Sciences, Health Campus, Universiti Sains Malaysia, 16150 Kubang Kerian, Kelantan, Malaysia.

Introduction

Hirschsprung's disease (HD) is generally synonym with paediatric age group congenital problems, in which 1 in 5,000 live births present in infant or early childhood. Frederick Ruysch has published an autopsy report "Enormis intestine coli dilatation" in 1691 regarding Hirschsprung's disease (1). In the 19th century, the pathogenesis of the disease was recognized where there was an absence of ganglion cells in the myenteric plexus of Auerbach and the submucosal plexus of Meissner.

However, adult Hirschsprung's disease incidence is unknown due to frequently unnoticed in the adult population. Majority present with short a segment type. The term adult Hirschsprung's disease is used for the patient older than 10 years old by some authors but the majority defined adult Hirschsprung's disease when it occurs after age 18 or 19 years. The male to female ratio is 4:1 with age ranging from 10 to 73 years old. 50% of the patients are less than 30 years old with an average age of 24.1 (2).

Histopathology examination typically shows different length of congenital aganglionosis submucosally and myenteric neural plexuses involving the rectosigmoid or rectum. The aganglionic segment in Hirschsprung's disease persistently contracted whether in adult or paediatric, but the proximal segment peristalsis were not affected that leads to hypertrophy and dilatation (megacolon) of the colon proximally. If this not treated or detected it might cause perforation of the proximal dilated normal colon.

Diagnosis

The diagnosis of adult HD is more difficult and challenging compared to paediatrics age group due to higher incidence of short or ultra-short segment aganglionosis. Different diagnostics criteria have been used and described by some authors, but the classic combination are still the same such as clinical, radiological and histopathologic findings. The typical presentations for adult Hirschsprung's disease consist of long-standing constipation either since birth, infancy, or childhood but there were patients who presented in the late adulthood. Patients can present with abdominal discomfort, distention and pain which is the most common presentation. During abdominal examination, palpable fecal masses, fecal impaction with or without tenderness can be felt due to chronic constipation. In adult HD, patients commonly present with milder disease, undiagnosed early and these patients have minimal relieve of the constipation by taking cathartics, chronically using enemas or digital evacuation. Later, they developed worsening constipation or fecal retention. The rarity of adult HD makes the clinician unaware or misdiagnosed them with chronic constipation, especially those with ultra short HD. That is why all patients presented with severe chronic constipation since birth or childhood need proper and detail evaluation to rule out HD.

There are modalities for diagnosis such as plain abdominal radiography, barium enema and/or manometry including rectal biopsy. Plain abdominal radiography only demonstrates findings that normally seen in most other small bowel obstructions which are

gaseous distension whether in colon and/or small bowel. Apart from variable gaseous, plain radiography sometimes show air-fluid levels and also huge retention of feces in colon especially sigmoid, upper rectum and absent gas in the lower rectum (Fig. 1). Barium enema study shows a clear-cut transition zone between the aganglionic, narrow or of normal caliber distal segments, and the dilated proximal colon that has normal ganglion cells (Fig. 2). The transition zone of the dilated segment is commonly described as funnel shaped or inverted cone. Although the transition zone can be a very reliable sign, absent of this sign does not rule out HD. Other possible reliable signs include retention of barium contrast and also mixing of barium and stool and rectal narrowing. About three quarters of patients can demonstrate such findings in barium enema. However, approximately 20% of the patients with adult HD, show dilated colon without characteristic rectal narrowing. These findings can be due to a short, or more commonly, an ultrashort segment. Another modality, anorectal manometry typically demonstrates absent or poor internal anal sphincter relaxation after rectal distension during manometry. Ultimately, rectal biopsy is required to make a definitive diagnosis, taken from the narrowed segment. Typical histology will show absence of ganglion cells with hyperplasia, hypertrophy of nerve fibers with an increased level of enzyme acetylcholinesterase. The role of computed

tomographic scan in adult HD is basically for an anatomical delineation and to rule out other causes.

Treatment

Surgical management of HD is very effective with satisfactory long-term results and quality of life. Different types of the corrective surgical procedures for HD had been suggested such as Swenson, Duhamel, Soave, and Lynn procedures. Besides, some surgeons suggest performing low anterior or ultralow anterior resection. A few corrective surgical procedures developed to treat the children have been applied to adults, but not all procedure is suitable for adult. Lynn procedure for posterior anorectal myectomy was advocated earlier as an approach or complement approach to short segment HD because of low morbidity and minimal technical difficulty. The

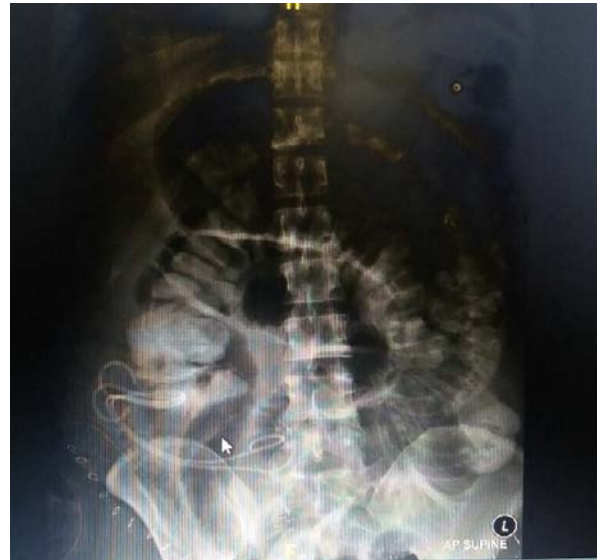

Figure 1: Abdominal X-ray in adult Hirschsprung's disease

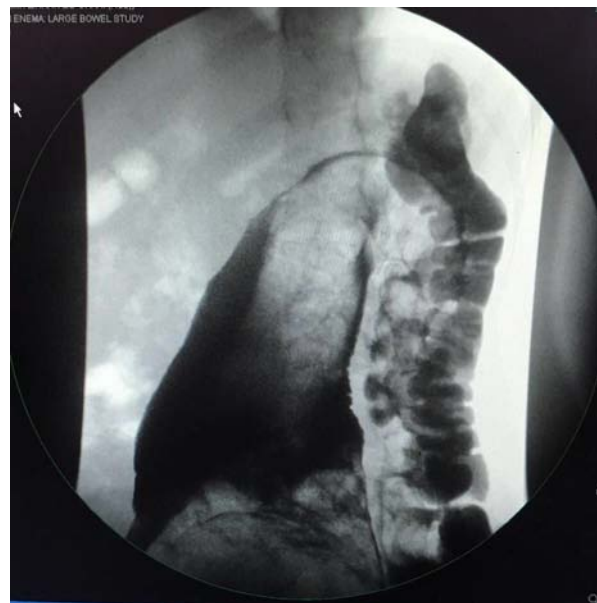


Figure 2: Barium enema in adult Hirschsprung's disease

combination anorectal myectomy and anterior resection procedure show promising excellent results with no major complications (2).

Dilemmas

The rarity of the disease makes the management difficult in adults due to the higher presentation of short or ultrashort segment with relative mild symptoms especially in the early stage of the disease. Constipation and acquired megacolon presented in

adults can be due to other causes such as neoplasm, slow colonic motility, volvulus, stricture, anatomical or functional outlet obstruction, Chagas disease or idiopathic (non-Hirschsprung's) megacolon. Common factors also can contribute to constipation that we always forget to assess in clinical review, for example dietary factors, medications, psychologic factors, and systemic diseases. Thorough clinical assessment before proceeding to investigation is necessary if there is a reasonable doubt regarding diagnosis.

Adult HD tends to have long standing problems with large caliber of colon, thick tissue and higher morbidity such as anastomotic stricture, leak and fistula. Early days surgeons like to perform 3 stage procedures, but now, it is clear the advantage of one stage procedure. The shift to one stage procedure prevents additional unnecessary surgical procedures, stoma-related complications, extra scar formation and

complications that can arise from the operation. As in adult HD, one of the choices was two stage procedures possibly the best to reduce complication. Looking from the limited number of cases and our own experience in adult HD, Duhamel procedure was associated with a lower rate of major postoperative complications compared to other procedures which is consistent with reports in the literature.

References

1. Leenders E, Sieber WK. Congenital megacolon observation by Frederick Ruysch—1691. *J Pediatr Surg.* 1970;5(1):1-3.
2. Miyamoto M, Egami K, Maeda S, Ohkawa K, Tanaka N, Uchida E, Tajiri T. The characteristic Hirschsprung's disease in adults: Report of a case and review of the literature. *J Nippon Med Sch.* 2005;72(2):113-20.