

Case Report

Therapeutic and Tectonic Penetrating Keratoplasty- All in One

Ng WL, Umi Kalthum MN, Jemaima CH, Then KY

Department of Ophthalmology, Faculty of Medicine, Universiti Kebangsaan Malaysia Medical Centre, Jalan Yaacob Latif, Bandar Tun Razak, 56000 Cheras, Kuala Lumpur, Malaysia.

Abstract

A middle-aged gentleman with history of left penetrating keratoplasty presented with left eye perforated corneal graft secondary to infective keratitis. The affected eye was blind from absolute steroid-induced glaucoma. In view of expected poor graft survival in a blind eye, globe removal was offered. However, the patient refused the treatment and request for another corneal graft. This case highlights both the possibility of good outcome of cornea graft in such a case, and also illustrates that patient's autonomy to refuse treatment option outweighs beneficence.

Keywords: Penetrating keratoplasty, blind, globe removal

Correspondence:

Umi Kalthum Md Noh, Department of Ophthalmology, Faculty of Medicine, Universiti Kebangsaan Malaysia Medical Centre, Jalan Yaacob Latif, Bandar Tun Razak, 56000 Cheras, Kuala Lumpur, Malaysia. Tel: +603-91455949 Fax: +603-91456672. Email: umi_fizul@yahoo.com

Date of submission: 16 Dec, 2014

Date of acceptance: 23 Apr, 2015

Introduction

Cornea disease is a common cause of blindness in developing countries (1). Isolated corneal surface blindness is amenable to treatment by replacing the diseased cornea tissue with a donor's graft. The procedure, coined as penetrating keratoplasty (PK), is indicated for tectonic, therapeutic, diagnostic or optical purposes. Perforated cornea graft due to infective ulcer is possible because of reduced corneal integrity in grafted cornea, however evisceration is usually the treatment option in cases of an already blind eye. We report a case of a successful outcome of a second cornea graft in a chronic corneal perforation, and secondary infection. Although, vision is not the main objective in this case, our patient is satisfied with the cosmetic results.

Case Report

A 59-year-old healthy Chinese gentleman presented with painless erythema of the left eye following a blunt trauma to the eye two months previously. It was progressive in nature but the patient did not seek any treatment beforehand. He had a history of left penetrating keratoplasty done three years ago for

contact lens-related cornea ulcer. He developed as secondary glaucoma with eventual blindness.

At presentation, there was periocular erythema with a large perforated cornea on the left non-seeing eye. The edge of the perforation was fluffy, with obvious stromal abscess. It was difficult at that stage to ascertain infective fungal component, as there was no satellite lesion and endothelium of cornea was not visible (Fig. 1). The anterior chamber (AC) was completely flat, and intraocular lens (IOL) was visible through the melted cornea.

Because of high possibility of chronic infection and perforated cornea in a blind eye, the patient was counseled for evisceration. However, he refused removal of the globe and insisted for another cornea graft, despite being well-informed on the high possibility of graft rejection and melt. Furthermore, he was willing to take the risk of intracranial extension of infection which may result from the delay incurred by waiting for donor cornea from the United States.

After repeated careful consultation, the patient was given intensive topical antibiotic and systemic

antibiotic and antifungal treatment. Gram stain and culture did not grow any microorganism, but patient's condition did not deteriorate with the treatment. A week later, PK was performed, utilizing a large corneal button to cover for the original defect and maximum removal of stromal abscess. Intraoperatively, removal of the pseudophakic lens was performed, with anterior vitrectomy and generous intravitreal irrigation with antibiotic and antifungal.

The removed corneal button and vitreous tap also did not grow any bacterial or fungal organism. He was given topical antibiotic, topical antifungal and topical steroid post-operatively, and was discharged a few days later. Three months later, the graft showed good corneal clarity and integrity (Fig. 2a, 2b). The patient was happy with the cosmetic outcome of the procedure.

Discussion

In Malaysia, the common indications for PK include pseudophakic bullous keratopathy, cornea scarring following infection, trauma, keratoconus, failed corneal graft and corneal dystrophy(1). The common indications for PK differ slightly only in terms of the orders of occurrence from the other countries worldwide (1). Those common indications mentioned are still the leading indication of PK. Gross corneal perforation, especially secondary to infection is managed with a therapeutic PK, if the patients still have some vision. However, for such condition which occurs in a blind eye, evisceration or enucleation is the usual approach (2), especially in areas where cornea tissues for grafts are not readily available. Furthermore, corneal graft performed on a chronically infective corneal ulcer is fraught with complications such as corneal melt, graft rejection and re-infection.

Many factors governed the success and survival rate of cornea transplant. Indications for operation, post-

operative care, ocular morbidity and presence of cornea infection are just but a few parameters that determines the outcome of corneal graft. A study looking at one year survival rate of therapeutic graft suggested a wide range of success rate, from 43% to 76%. The same study found that compliance to post-operative care and causative organism are of major importance in achieving a successful surgery. However, therapeutic grafts had the lowest five year survival rates compared to other indications of PK, (3) which are optical, diagnostic or cosmetic purposes.

The major principles in therapeutic PK include excision of devitalized and infected tissue, anterior vitrectomy and restoration of structural integrity as part of tectonic purpose (4,5). The vision was not considered in this case but the preservation of integrity of globe and eradication of infective process are the aims. The dilemma arises when patient insisted for a re-graft despite being repeatedly informed on the possible sequelae and adverse reactions that may

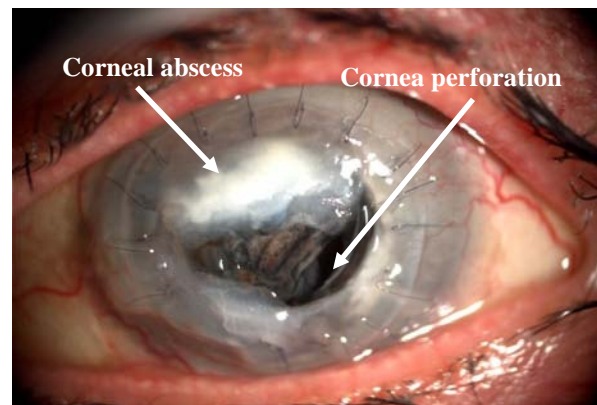


Figure 1: Large perforated corneal graft with abscess, melting inferotemporal peripheral cornea and impending drop out of intraocular lens.

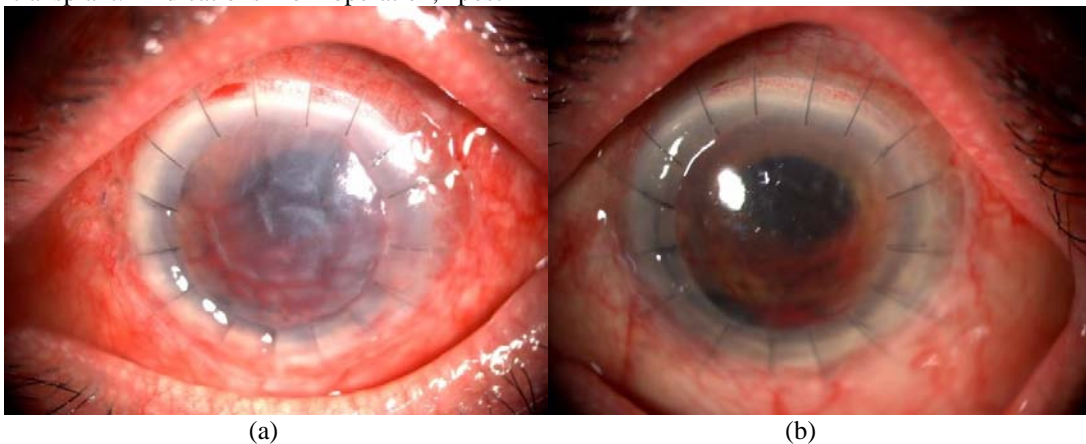


Figure 2: a) Photograph showing the appearance of graft at Day 1 post-PK, and b) at Week 8 post- PK, showing clearer graft and intact sutures.

ensue. Furthermore, the delay to perform corneal graft which is caused by waiting for graft to arrive from donor country, may lead to worsening of pre-existing infection or life-threatening intracranial extension of primary infection. Despite all these, patient's autonomy dictate the course of management taken in this case.

The corneal graft showed a very good clarity of the button, with no signs of corneal melt or further re-infection. Irrigation with antibiotic and antifungal agents are important steps to ensure sterility of the eye in such cases. Although the gram stain and culture did not show positive growth, clinical judgment precedes. Chronic endophthalmitis usually results from gram positive bacterial infection. Additionally, fungal invasion may contaminate the primary infection, especially in chronic cases or long term, injudicious antibiotic use. Hence, prophylactic and empirical treatment guided by clinical judgement is an important aspect in certain cases.

An analysis of the relative success and complications of PK in perforated eyes found no significant difference between sterile perforated cornea and infected eyes which perforate, suggesting that the major risk factor is perforation itself (6). The success rate of PK in maintaining structural integrity was almost 85% in a study (3), although the cases were not exclusive of infected conditions only, which may explain the good result. The issue of managing PK performed for pre-existing infection is the steroid use. Corticosteroid is an important component of post-operative care, to minimize the risk of graft rejection. However, reducing the inflammation of the eye would also mean reducing the immune response, and necessarily the defense against infection. The use of topical steroid in a fungal-infected cornea is debatable and definitely requires very close monitoring of recurrence of infection.

The size of corneal grafts matter. The usual graft size utilized is between 7.0 mm to 8.5mm, (4) also putting into consideration the amount of tissue that needs to be removed. Smaller grafts may not always be suitable as pre-existing abscess is usually large, and optical quality will also be compromised. On the other hand, larger grafts tend to result in complications such as postoperative anterior synechiae, vascularization and secondary glaucoma. The optimal size depends on the

size of diseased tissue, the size of patients' cornea and surgeons' preference, to name a few. Eventually, post-operative care and close tailoring of medications according to patients' condition play a central part in determining graft survival.

Conclusion

Penetrating keratoplasty versus evisceration in managing severely infected and perforated cornea graft is debatable for blind eye. The quality of donor cornea, surgical procedures and postoperative care play important roles in determining the success rate of the PK. Eventually, patient's autonomy to refuse treatment option always outweighs beneficence. A proper documentation and patient's counseling is mandatory to prevent legal implication in the future.

References

1. Reddy SC, Tajunisah I. Indication for penetrating keratoplasty in west Malaysia. *Int J Ophthalmol* 2008; 1(2): 125-8.
2. Mansoor Q, Qamar RR, Biswas S, Adhikary HP. Long-term follow up of corneal and sclera-corneal grafting in severe eye perforations. *Pak J Ophthalmol* 2006; 22(2): 92-7.
3. Aparna C Varghese DO, Aneeta Jabbar MS, Reesha KR. Outcome of a large series of penetrating keratoplasties in a tertiary eye care centre- A 6 year retrospective study. *Kerala Journal of Ophthalmology* 2011; 23(1):47-51.
4. Balabanov C, Murgova S, Parashkevova B. Treatment of perforated infectious corneal ulcers with penetrating keratoplasty. *Journal of IMAB* 2007; 13(1):35-39.
5. Taylor DM, Stern AL. Reconstructive keratoplasty in the management of conditions leading to corneal destruction. *Ophthalmology* 1980; 87(9):892-904.
6. Kirkness CM, Ficker LA, Steele AD, Rice NS. The role of penetrating keratoplasty in the management of microbial keratitis. *Eye (Lond)* 1991; 5(Pt 4): 425-31.