

## Case Report

# Circumaortic Left Renal Vein and Double Right Renal Vein: A Case Report

Naveen K, Ravindra S (✉), Satheesha NB, Mohandas Rao KG, Ashwini AP, Jyothsna P

Department of Anatomy, Melaka Manipal Medical College (Manipal Campus), Manipal University, Manipal, 576104 Karnataka, India.

### Abstract

Venous malformation of the kidney is not uncommon. However, bilateral variation of renal veins is of rare occurrence and is clinically significant. In the present case, left renal vein divided into left pre and retro-aortic renal veins which passed in front and behind the abdominal aorta respectively, together forming a circumaortic renal vein. The retro-aortic limb received left testicular vein at a distance of 5.8 cm from inferior vena cava and pre-aortic vein received left suprarenal vein at a distance of 4.2 cm from inferior vena cava. Pre-aortic and retro-aortic veins drained into IVC separately about 4 cm apart from each other. On the right side, two separate renal veins (superior and inferior) were present. Both of them drained into inferior vena cava separately and about 2.6 cm apart from each other. This aberrant pattern of renal vein may affect the venous drainage of kidney and testis leading to renal hypertension and varicocele. Such variations should be known to urologists and surgeons before commencing any surgical and interventional procedures.

**Keywords:** Renal veins, inferior vena cava, aorta

### Correspondence:

Ravindra Swamy, Department of Anatomy, Melaka Manipal Medical College (Manipal Campus), Manipal University, Manipal, 576104 Karnataka, India. Tel: 09986869220 Fax: 91-820-2571905 Email: ravindrammmc@gmail.com

Date of submission: 20 May, 2014

Date of acceptance: 31 Dec, 2015

### Introduction

Bilaterally each kidney is drained by a single renal vein opening into the inferior vena cava (IVC) at the level of L2 vertebra. The right renal vein is shorter as compared to left renal vein and does not receive any other tributaries, whereas the left renal vein crosses the abdominal aorta anteriorly and opens into inferior vena cava after receiving left suprarenal vein and left gonadal veins (1).

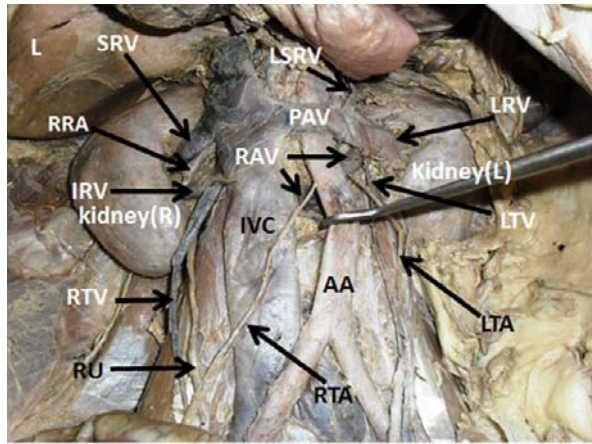
Presence of accessory renal veins is not uncommon, but its existence may remain unnoticed and can be found only during venography, surgery or autopsy. Accessory renal vein on left side when persists, infrequently forms 'circum aortic' in which, one vein passes anterior and other posterior to the aorta on the way of their termination. This appearance is also known as persistence of renal collar (1). Prevalence of accessory renal veins on the right side is much higher than the left side. This could be due to complex

embryogenesis involving the shifting of venous arrangement to the right during vascular formation likely to deject any retention of accessory left sided renal veins (2).

Retroperitoneal surgeries like abdominal aortic aneurysm surgery, renal transplantation etc. need a detailed preoperative renal vascular observation. A renal vascular variation can lead to iatrogenic fatal hemorrhage during operation which makes it obligatory not to overlook any kind of aberrant vascular pattern. Although numerous renal vascular variation are mentioned in literature, there is almost no case reported regarding the bilateral renal vein variation of combined circumaortic renal collar on left side and double renal vein on the right side.

### Case Report

During cadaveric dissection for undergraduate medical students we came across bilateral variation of renal

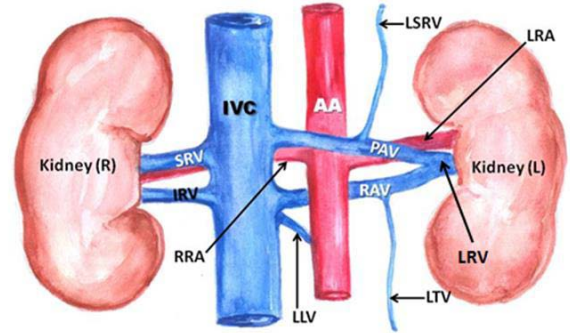


**Figure 1:** Photograph showing bilateral variant renal venous pattern. On the left side, presence of circumaortic vein with pre-aortic renal vein (PAV) in front and retro aortic renal vein (RAV) passing behind the abdominal aorta (AA), along with left testicular vein (LTV) draining into RAV and left suprarenal vein (LSRV). On the right side, superior renal vein (SRV) and inferior renal vein (IRV) draining the right kidney can be seen. RTA – right testicular artery, LTA - Left testicular artery, IVC - inferior vena cava, RTV - right testicular vein, RU - right ureter, RRA- right renal artery, LRV – left renal vein, L – liver.

veins in formalin embalmed adult male cadaver aged about 60 years. Arising from the left kidney, the left renal vein (LRV) divided into two veins, one pre-aortic vein (PAV) and another retro aortic vein (RAV) which passed in front and back of the aorta respectively forming circumaortic renal vein (Fig. 1, 2). The circumaortic renal vein on the left side received the left suprarenal vein (LSRV) to its pre-aortic limb at about 4.2 cm from the inferior vena cava, and left testicular vein (LTV) to retro aortic limb at a distance of 5.8 cm from the inferior vena cava. In addition to this, third left lumbar vein (LLV) also drained into the left retro aortic renal vein (RAV) just before its termination into inferior vena cava (IVC) (Fig.1, 2). Both of PAV and RAV eventually drained into IVC separately about 4 cm apart from each other. On the other side, we found two right renal veins, superior renal vein (SRV) and inferior renal vein (IRV) emerging from the corresponding part of hilum of right kidney. Both superior and inferior renal veins drained into IVC about 2.6 cm apart from each other.

## Discussion

Bilateral renal venous malformation with circumaortic left renal vein (CLRv) and accessory right renal veins can be rarely seen together. A wide variety of renal vein variations have been reported. Literature reviews have mentioned different patterns of renal vein variations earlier. Natsis et al. classified the different



**Figure 2:** Diagrammatic representation of the variation: LRV: left renal vein, LSRV: left supra renal vein, PAV: preaortic vein, RAV: retroaortic vein, LLV: third left lumbar vein, SRV: superior renal vein, IRV: inferior renal vein, LTV: left testicular vein, RRA: right renal artery, LRA: left renal artery, IVC: inferior vena cava, AA: abdominal aorta.

pattern of circumaortic left renal vein into types I, II and III. In Type I, a pre-aortic and retroaortic vein after splitting from left renal vein passes medially and drains into inferior vena cava. In Type II, separate pre-aortic and the retroaortic left renal veins drains in inferior vena cava. In Type III there is anastomoses between the pre-aortic and retroaortic vein or without anastomoses there is presence of multiple pre-aortic or retroaortic renal veins. According to this, the present pattern can be considered as type I, in which the left renal vein splits into a pre-aortic and retroaortic branches and at last drains into the inferior vena cava (3).

A study conducted by Anupama et al., reported 6.6% of prevalence of CLRv among 58% cases of renal vein variations (2). Beckmann and Abrams reported remarkably higher prevalence (11%) of CLRv as detected by venograms and autopsy (4). Yesildag et al. reported that prevalence of CLRv is 0.3 to 3.7% in Turkish population (5). The incidence of CLRv was 7% of cadavers donated for anatomy as stated by Hashizume et al. (6). Yi et al. reported that the median incidence of CLRv was 7.0% in cadavers examined, and 1.8% in clinical cases examined (7). Existence of CLRv can also be associated with pathological conditions as with abdominal aortic aneurysm (6) and also with congenital organ anomalies like horseshoe kidney (8).

Developmentally, bilateral cardinal venous system and associated venous channels becomes unilateral right sided IVC around 8th week of development. Primarily two renal veins are present on both sides as ventral and

dorsal plane. Eventual union of both tributaries results in the single vessel formation where as its persistence leads to the existence of accessory or additional renal vein (9). Based on the developmental discrepancies, Nam et al., in their research report on the clinical significance of retro-aortic left renal vein, mentioned 4 types of variant pattern of left renal vein. In type 1, there is obliteration of ventral pre-aortic limb of left renal vein and the persistent dorsal retro-aortic limb drains into IVC. In type 2-ventral pre aortic limb regresses, but dorsal limb transforms into retro-aortic left renal vein drains into IVC. In type 3- persistence of sub-surpacardinal anastomoses, inter supra-cardinal anastomoses and the dorsal limb of left renal vein together forms the CLRV and opens into IVC. Type 4 is similar to type 2 but drains into left common iliac vein instead of IVC (10).

The left testicular vein draining into the retroaortic renal vein as seen in the present case, can lead to the varicocele (11). If the retroaortic vein is compressed as it is passing in between the aorta and the lumbar vertebrae, risk of varicocele is relatively higher as the venous blood reroute from left testicular vein to retroaortic vein, left renal vein, preaortic vein and at last into inferior vena cava in a highly complex course.

One of the previous studies has reported the presence of additional renal veins in 3.3% cases on right side and in 2.6% on left (12). Awareness on the presence of double renal veins is handy for the angiographers, radiologists during catheter design and planning portorenal shunt and to transplant surgeons.

During abdominal aortic surgery, unexpected venous trauma due to variant renal veins is a major problem to surgeons (13). CLRV may pose higher risk of venous injury in patient as the surgeon overlook the retroaortic component leading to hemorrhage and death during retroperitoneal surgery (2). Preoperative diagnosis of CLRV is still difficult (8). The detection rate of circumaortic left renal vein is about 0.9%–6.3% by multi-slice CT scan or MRI and thus it is suggested that angiography is superior to CT and MRI in diagnosis of a CLRV (13). Knowledge of CLRV is important when blood samples are collected from the adrenal or renal veins (4). Thus radiologists, surgeons and clinicians need to have an idea of such variations.

## Conclusion

Unique combination of bilateral aberrant renal veins with CLRV and double renal veins on right side as in the current case may pose variety of clinical complications at different stages of therapeutic approaches. Adding to this, draining of left testicular

vein into highly susceptible retroaortic renal vein may further worsen the condition by manifesting varicocele and testicular dysgenesis etc.

## References

1. Standring S. Gray's Anatomy-The anatomical basis of clinical practice. 39th Ed. Elsevier: Churchill Livingstone, 2005, pp 1274-6.
2. Gupta A, Gupta R, Singal R. Congenital variations of renal veins: embryological background and clinical implications. *J Clin Diagn Res* 2011; 5:1140-3.
3. Natsis K, Tsitouridis I, Totlis T, Levva S, Tsikaras P, Skandalakis P. Proposal for classification of the circumaortic renal collar's morphology. *Am Surg* 2008; 74(12): 1190-4.
4. Beckmann CF, Abrams HL. Circumaortic venous ring: incidence and significance. *AJR Am J Roentgenol* 1979; 132(4): 561-5.
5. Yesildag A, Adanir E, Koroglu M, Baykal B, Oyar O, Gulsoy UK. Incidence of left renal vein anomalies in routine abdominal CT scans. *Tani Girisim Radyol* 2004; 10(2): 140-3.
6. Hashizume K, Taniguchi S, Ariyoshi T, et al. Circumaortic left renal vein associated with juxtarenal abdominal aortic aneurysm. *Ann Vasc Dis* 2013; 6(3): 658-61.
7. Yi SQ, Ueno Y, Naito M, Ozaki N, Itoh M. The three most common variations of the left renal vein: a review and meta-analysis. *Surg Radiol Anat* 2012; 34(9): 799-804.
8. Iimura A, Oguchi T, Shibata M, Matsuo M, Takahashi Y, Takahashi T. Morphological observation of the horseshoe kidney with circumaortic venous ring. *Okajimas Folia Anat Jpn* 2012; 89(3): 67–74.
9. Monkhouse WS, Khalique A. The adrenal and renal veins of man and their connection with Azygos and lumbar vein. *J Anat* 1986; 146: 105-15.
10. Nam JK, Park SW, Lee SD, Chung MK. The clinical significance of a retroaortic left renal vein. *Korean J Urol* 2010; 51(4): 276-80.
11. Scultetus AH, Villavicencio JL, Gillespie DL. The nutcracker syndrome: its role in the pelvic

- venous disorders. *J Vasc Surg* 2001; 34(5): 812-9.
12. Satyapal KS, Haffejee AA, Singh B, Ramsaroop L, Robbs JV, Kalideen JM. Additional renal arteries: incidence and morphometry. *Surg Radiol Anat* 2001; 23(1): 33-8.
  13. Shindo S, Kubota K, Kojima A, et al. Anomalies of inferior vena cava and left renal vein: risks in aortic surgery. *Ann Vasc Surg* 2000; 14(4): 393-6.