

Case Report

Unusual Termination of Facial Artery Associated with the Presence of Premasseteric Branch- A Case Report

Abhinitha P, Naveen K, Jyothsna P, Mohandas Rao KG, Satheesha NB, Venumadhav N, Swamy Ravindra S

Department of Anatomy, Melaka Manipal Medical College (Manipal campus), Manipal University, Madhavanagara, Udupi District, 576104 Karnataka State, India.

Abstract

Face being highly vascular region essentially receives extensive blood supply from the facial artery. Facial artery frequently shows variation in its pattern of origin, course and termination. An unusual premasseteric branch is the one among its variant branches on the face. We report herewith the untimely termination of facial artery as alar artery at the nose instead of medial angle of the eye associated with an abnormally large posterior branch known as premasseteric branch. Presence of premasseteric artery may be considered as beneficial in 'raising flap' approaches. However, ascertaining its existence makes obligatory for the surgeons during surgical procedures of the face.

Keywords: Facial artery, posterior branch, premasseteric branch, raising flap

Correspondence:

Naveen Kumar, Department of Anatomy, Melaka Manipal Medical College (Manipal Campus), Manipal University, Madhavanagara, Udupi District, 576104 Karnataka State, India. Tel: +919880548636 Fax: 0820-2571201 Email: naveentonse@gmail.com

Date of submission: 10 Jan, 2014

Date of acceptance: 17 June, 2014

Introduction

Facial artery is the chief arterial source of the face, arising as a branch from external carotid artery in the carotid triangle of the neck, just above the tip of the greater cornua of hyoid bone. After the looped course in the submandibular region, it gains its entrance on the face by winding the lower border of the body of the mandible. On the face, it is accompanied posteriorly by the facial vein. In the face, the artery exhibits tortuous course in order to allow the mobility of the structures overlapping it. It courses upwards and forwards, close to lateral to the angle of mouth, then along the side of the nose to the medial angle of eye. Here, it ends by anastomosing with the dorsal nasal branch of ophthalmic artery (1).

In the face, it normally gives off three named branches which are superior labial, inferior labial and lateral nasal branches. There may be few unnamed smaller branches as well. However, the prominent premasseteric or

posterior branch of the facial artery is a rare branch. Occasionally, its labial branches may be absent or under developed unilaterally. In such cases, contralateral counterpart vessels provide the vascular supply to the region (2). Presence of premasseteric branch of facial artery may be beneficial during cranio-facial surgical approaches to raise the muscle flaps safely (3) provided, prior notice of its existence and detailed anatomy, failure to which, might lead to irreversible complications involving aesthetic of the face.

Case Report

During routine dissection of the face, a unilateral variation of the facial artery was found on the left side of the face of a male cadaver aged between 60-65 years. Facial artery took its normal origin from external carotid artery in the carotid triangle and had normal appearance on the face. However, its termination was found to be untimely at the nose as alar artery. On the face, it gave premasseteric branch 2

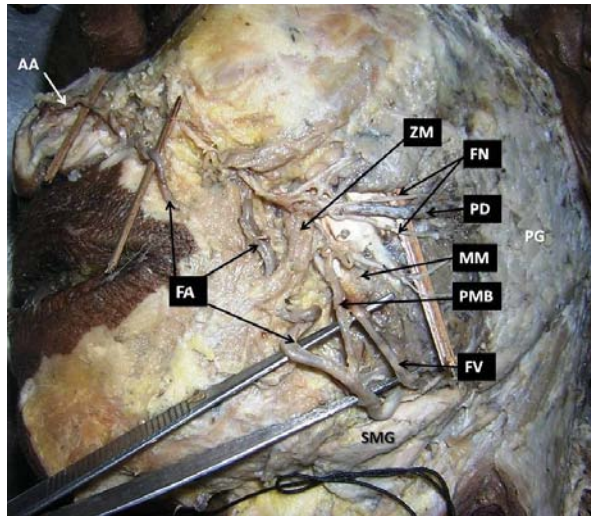


Figure 1: Dissection of left side of the face showing branching and termination of facial artery (FA) as angular artery (AA). PMB: premassesteric branch given anterior to masseter muscle (MM). FV: facial vein, PG: parotid gland, PD: parotid duct, SMG: submandibular gland, ZM: zygomaticus major, FN: facial nerve branches.

centimetres above the base of the mandible, 2cm anterior to masseter muscle. From its origin, it ran upwards, obliquely along the anterior border of the masseter (Fig. 1). Near the insertion of masseter, it divided into anterior and posterior terminal branches (Fig. 2). The anterior branch ran between zygomaticus major and masseter. It then turned medially, pierced buccal pad of fat, buccopharyngeal fascia and supplied the buccal region. The posterior division assumed tortuous course, ran posteriorly and ended by supplying the masseter.

Discussion

Facial artery, a chief nutritional source of the face, often shows variation in its morphology. There have been extensive studies on its pattern of origin, course and termination associated with variant branching pattern. Authors have been trying to standardize the mode of variation in terms of definitive classification. However, it has been observed that, different authors are claiming their own way of classification.

Niranjan has reported the overall incidences of abnormal termination of facial artery without categorising them as definite groups (4). According to their observation, the facial artery ended as angular artery (68%), lateral nasal artery (26%), superior labial artery (4%) and in 2% of cases it terminated at alar base of the nose. Loukas et al. reported their findings of variant pattern of termination of facial arteries into

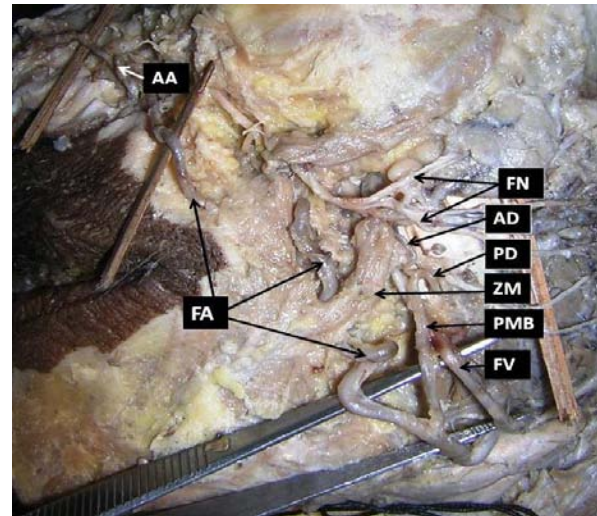


Figure 2: Closer view of course of facial artery (FA) and premassesteric branch (PMB) on face, the premassesteric branch dividing into anterior (AD) and posterior (PD) divisions. AA: Angular artery, FV: facial vein, ZM: zygomaticus major, FN: facial nerve branches.

five categories, which has been summarized in Table 1 (5). According to this pattern, the present case falls into type D category. The present variation is rare of its kind and hence reporting such case is clinically noteworthy.

Bayram and Kalaycioglu performed the study on facial arterial anatomy on foetal face and categorised its mode of termination into three categories (6). Type 1 category – facial artery terminated as angular artery, Type 2 category- facial artery terminated as superior labial artery, Type 3 category- Facial artery terminated as inferior labial artery. A study carried out by Lohn et al. reported the termination of facial artery as lateral nasal artery and as transverse facial artery in 49% and 5% of cases respectively (7).

Masseter muscle is supplied by the masseteric branches of the maxillary, facial and transverse facial artery (8). Presence of premassesteric branch provides an additional source of nutrition. Similar case of premassesteric branch of facial artery but with the tortuous course was reported by Kumar et al. (2). In this case, the premassesteric branch was reported to be terminated by anastomosing with the infra-orbital artery. It has been also named as posterior branch of the facial artery. An extensive study carried out by Magden et al. reported that in 3% of cases, the diameter of the premassesteric branch was larger than the facial artery when present (3). Apart from the origin of unusual branches like premassesteric branch, the facial artery may also give origin to rare arteries

Table 1: Summary of categorization of variant pattern of termination of facial arteries by Loukas et al., (5)

Types	Description of termination	Incidence
A	bifurcating into superior labial and lateral nasal arteries	47.5%
B	superior labial and lateral nasal with the lateral nasal continuing as superior alar artery	38.7%
C	superior labial artery	8.4%
D	facial artery ending as superior alar artery	3.8%
E	facial artery terminated as a rudimentary twig without providing any significant branches	1.4%

such as ascending pharyngeal, superior laryngeal, tonsillar or maxillary branches (9).

Premasseteric branches of the facial artery when present; generally establish anastomosis with neighbouring arteries like branch of transverse facial artery (37% cases), buccal branch of maxillary artery (22% cases) (3). According to Pinar et al. the anastomosis between premaxillary and transverse facial arteries, when present, usually lies on the masseteric fascia (10). This anastomotic establishment is beneficial in surgical flap removal procedures.

Masseter muscle is often targeted in rehabilitation of facial palsy, tumour excision of parotid gland in addition to traumatic lip defect repairs. Since the premaxillary branch of facial artery supplies the masseter muscle it is imperative to have adequate knowledge of morphology of the facial artery (11). Apart from this, it is also important during surgical interventions as in applying botulinum toxin-A, during the correction of the benign masseteric hypertrophy, mandibular angle osteotomy (12).

The premaxillary branch of the facial artery in the present case was considerably a significant variation. Its presence and anatomical details must be noted carefully to avoid critical haemorrhage that occurs during surgical procedures involving masseter muscle resection. Ignoring its existence may eventually result in aesthetic related complications of the face.

References

- Datta AK. Essentials of Human anatomy (Head & Neck). 4th ed. Kolkata: Current Books International, 2006, pp-120-1.
- Kumar N, Nayak SB, Shetty S, Guru A. Unusual posterior (premaxillary) branch of facial artery – a case report. IJAV 2011; 4: 161-3.
- Mağden O, Göçmen-Mas N, Senan S, Edizer M, Karaçaylı U, Karabekir HS. The premaxillary branch of facial artery: its importance for craniofacial surgery. Turk Neurosurg 2009; 19(1): 45-50.
- Niranjan NS. An anatomical study of the facial artery. Ann Plast Surg 1988; 21(1): 14-22.
- Loukas M, Hullett J, Louis RG, et al. A detailed observation of variations of the facial artery with emphasis on the superior labial artery. Surg Radiol Anat 2006; 28(3): 316-24.
- Bayram SB, Kalaycioglu A. Branching patterns of facial artery in fetuses. The New Journal of Medicine 2010; 27: 227-30.
- Lohn JW, Penn JW, Norton J, Butler PE. The course and variation of the facial artery and vein: implications for facial transplantation and facial surgery. Ann Plast Surg 2011; 67(2): 184-8.
- Gray's Anatomy. Alimentary system. Section ed: Bannister LH; Cardiovascular system. Section ed: Giorgio Gabellan, 38th ed. London: Churchill-Livingstone, 1995, pp-1518-20.
- Bergman RA, Afifi AK, Miyauchi R. Compendium of human anatomical variations. Baltimore: Urban and Schwarzenber, 1988, pp- 65.
- Pinar YA, Govsa F. Anatomy of the superficial temporal artery and its branches: its importance for surgery. Surg Radiol Anat 2006; 28(3): 248-53.
- McCarthy JG. Plastic Surgery, Vol 3, USA: Saunders Company, 1990, pp-2286-90.
- Hwang K, Kim YJ, Chung IH, Song YB. Course of the masseteric nerve in masseter muscle. J Craniofac Surg 2005; 16(2):197-200.