

Case Report

Unusual Path of Branches of Ilioinguinal Nerve: A Clinically Important Anatomic Variant

Satheesha BN, Srinivasa RS (✉), Prakashchandra S, Surekha DS, Deepthinath R, Raghu J, Abhinitha P, Jyothsna P

Department of Anatomy, Melaka Manipal Medical College (Manipal Campus), Manipal University, Manipal. 567104 Karnataka State, India.

Abstract

Ilioinguinal nerve is a collateral branch of lumbar plexus. Its anatomical variations in relation to adjacent musculoaponeurotic structures play a crucial role in the development of neuropathies associated with lower abdominal surgeries. In this report, we present a rare case of unusual course and branches of the ilioinguinal nerve, in a 55-year-old male cadaver. In the lateral part of inguinal canal ilioinguinal nerve gave three branches. Two of its branches pierced the external oblique aponeurosis, about 6 cm above the pubic symphysis, to supply the skin of the lower part of the anterior abdominal wall. Another branch pierced the conjoint tendon, in the medial part of the inguinal canal about 2 cm above the superficial inguinal ring. Knowledge of unusual path of these branches may be important to avoid injuries during the surgical repair of groin hernias. Further care should be taken while dealing with the conjoint tendon in the Bassini procedure.

Keywords: Ilioinguinal nerve, aponeurosis, hernia, groin, variation

Correspondence:

Srinivasa Rao Sirasanagandlaar, Department of Anatomy, Melaka Manipal Medical College (Manipal Campus), Manipal University, Manipal. 567104 Karnataka State, India. Tel: 9886310652 Fax: +91-820-2571905 Email: seenaih.anat@gmail.com

Date of submission: 18 Mar, 2014

Date of acceptance: 27 Sept, 2014

Introduction

Ilioinguinal nerve (IIN) is a branch of lumbar plexus. It takes origin from the ventral ramus of L1. It emerges at the lateral border of the psoas major muscle, and runs across the quadratus lumborum muscle. Close to the anterior limit of the iliac crest, it pierces the transversus abdominis and internal oblique muscles. After this, it enters into the inguinal canal medial to the anterior superior iliac spine. In the canal, it accompanies the spermatic cord and leaves the canal by passing through the superficial inguinal ring. It supplies the small portion of both transversus abdominis and internal oblique muscles. It also provides cutaneous innervation to skin of the inguinal region, portion of the external genitalia and superomedial aspect of the thigh (1). IIN frequently shows variation in its origin, course and termination. The anatomic variants of the IIN are well documented in the literature (2,3,4,5,6). The anatomical

basis of IIN injury has also been studied while performing the surgical repair of inguinal hernias (4,5,6). Knowledge of occurrence of possible variations of IIN is surgically important to understand the pathology of neuropathies in inguinal region (6). In the present case, we report a rare case of IIN having unusual branching pattern in the inguinal canal and discuss its clinical importance.

Case Report

During regular dissection classes for medical undergraduate students, we came across a rare anatomical variation of IIN, in the left inguinal canal. It was observed in a 55-year-old male cadaver of south Indian origin. IIN pierced the internal oblique muscle medial to the anterior superior iliac spine and entered into the inguinal canal. In the canal it traversed about 1 cm above the inguinal ligament.

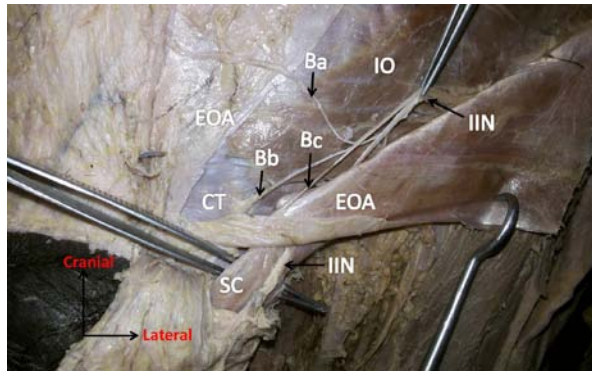


Figure 1: Dissection of left groin region showing the unusual path of branches of the ilioinguinal nerve (IIN). (Ba, Bb and Bc: branches of the IIN; SC: spermatic cord; CT: conjoint tendon; EOA: external oblique aponeurosis; IO: internal oblique muscle)

After a short course within the canal, it gave three branches. One of these branches traversed the canal along the main trunk. Close to the superficial inguinal ring, it perforated the aponeurosis of the external oblique muscle to supply the lower part of the anterior abdominal wall. Second branch also perforated the external oblique aponeurosis about 6 cm above the pubic symphysis. Third branch pierced the conjoint tendon after a short course in the canal. The main trunk of the IIN emerged from the superficial inguinal ring lying superolateral to the spermatic cord (Fig. 1 and 2).

Discussion

IIN is known to show variations in its origin, course and relationship with adjacent musculoaponeurotic structures (2,3,4,5,6). Moosman and Oelrich were the first researchers to describe the anatomical variations of the IIN in the inguinal canal (3). Salama et al. have demonstrated the possible variations of genital branches of the IIN, in the inguinal canal (4). Al-Dabbagh described the variant position IIN in relation to superficial inguinal ring and its risk during hernia repair (5). Various authors have reported the IIN perforating the external oblique aponeurosis (EOA) (4,6,7,8). The average distance of perforation of IIN from the superficial inguinal ring is about 2 cm (4,6). Perforation of EOA by one of the branches of IIN is extremely rare. In the present case, one of the IIN branch found to perforate the EOA, close to the superficial inguinal ring. The relation of IIN branch with the EOA may dispose it to risk during hernial repair (8). According to Moosman incision should be given at the upper margin of superficial inguinal ring (3). However, based on the current case, incision at the upper margin of superficial inguinal ring should not be encouraged as the risk of nerve injury will be more at this level.

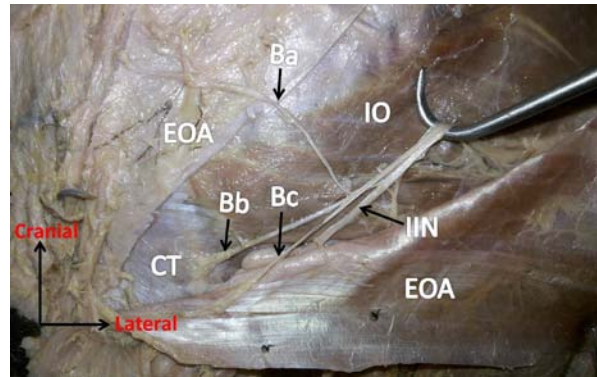


Figure 2: Closer view of left groin region showing the unusual path of branches of the ilioinguinal nerve (IIN). (Ba, Bb and Bc: branches of the IIN; CT: conjoint tendon; EOA: external oblique aponeurosis; IO: internal oblique muscle)

Another important observation of the present case is that one of the branches of IIN pierced the conjoint tendon. Knowledge of such branch during the surgical repair of the inguinal hernia is crucial while following the Bassini technique for the treatment of hernia repair. In this technique, hernia is relieved by suturing conjoint tendon to the inguinal ligament. While suturing care should be taken to avoid the entrapment of nerve in the suture (8). According to the classical textbook description, IIN will not give terminal branches in the inguinal canal. Moosman has also observed the same pattern wherein IIN will give branches at or below the level of superficial ring (3). Contrary to this, Salama et al. (4) and Ndiaye et al. (6) have reported high frequency of INN giving terminal branches in the canal. Though, the termination of IIN in the inguinal canal is not rare, its branches piercing the EOA and conjoint tendon are seldom reported. The anatomic variations of the IIN in relation to the surrounding musculoaponeurotic structures are clinically important. Injuries of this nerve during surgeries in lower abdominal region may lead to chronic neuropathies and diagnostic problems. Incidence of ilioinguinal nerve syndrome has been reported in 2-54% of cases (9). Prior knowledge of unusual course of the IIN branches reported here may be important to avoid postoperative neuropathies during inguinal hernia repair and lower abdominal surgeries.

References

1. Knockaert DC, D'Heygere FG, Bobbaers HJ. Ilioinguinal nerve entrapment: a little-known cause of iliac fossa pain. *Postgrad Med J* 1989; 65(767): 632-5.
2. Bergman RA, Afifi AK, Miyauchi M. *Illustrated Encyclopedia of Human Anatomic Variation: Opus III: Nervous System: Plexuses*. Ilioinguinal

- nerve.<http://www.anatomyatlases.org/AnatomicVariants/NervousSystem/Text/IlioinguinalNerve.shtml>. Last accessed on 13/03/2014.
3. Moosman DA, Oelrich TM. Prevention of accidental trauma to the ilioinguinal nerve during inguinal herniorrhaphy. *Am J Surg* 1977; 133(2): 146–8.
 4. Salama J, Sarfati E, Chevrel JP. The anatomical bases of nerve lesions arising during the reduction of inguinal hernia. *Anat Clin* 1983; 5(2): 75–81.
 5. Al-Dabbagh AK. Anatomical variations of the inguinal nerves and risks of injury in 110 hernia repairs. *Surg Radiol Anat* 2002; 24(2): 102-7.
 6. Ndiaye A, Diop M, Ndoye JM, et al. Anatomical basis of neuropathies and damage to the ilioinguinal nerve during repairs of groin hernias. (about 100 dissections). *Surg Radiol Anat* 2007; 29(8): 675-81.
 7. Roberts WH, Engen P, Mitchell D. A proposed method of dissection of the anterolateral abdominal wall--Applied features. *Anat Anz* 1983; 154(2): 111–7.
 8. Mandelkow H, Loeweneck H. The iliohypogastric and ilioinguinal nerves. Distribution in the abdominal wall, danger areas in surgical incisions in the inguinal and pubic regions and reflected visceral pain in their dermatomes. *Surg Radiol Anat* 1988; 10(2): 145-9.
 9. Poobalan AS, Bruce J, Smith WC, King PM, Krukowski ZH, Chambers WA. A review of chronic pain after inguinal herniorrhaphy. *Clin J Pain* 2003; 19(1): 48–54.