

Original Research Article**Comparative Study of Mandibular Cortical Index in Orthopantomogram and Bone Mineral Density of Lumbar Vertebrae in Dual Energy X-Ray Absorptiometry in Postmenopausal Females in North India**Rati G¹, Puja C (✉)¹, Sunita K², Shashi M¹, Alok KC¹, Anurag¹¹Department of Anatomy, Shri Guru Ram Rai Institute of Medical and Health Sciences, Patel Nagar, Dehradun, 248001 Uttarakhand, India.²Department of Anatomy, Universty College Medical Sciences, 110095 New Delhi, India.**Abstract**

Osteoporosis is a bone disorder which results in low bone mineral content leading to recurrent fractures commonly seen in females after menopause. Few studies have proposed the use of orthopantomogram as a diagnostic marker for osteoporosis as it is simple, quick, easy, inexpensive, non-invasive and widely used. Present study was undertaken to assess the efficacy of OPG to diagnose osteoporosis apropos bone densitometry (DEXA).The study comprised of fifty post-menopausal females who were subjected to panoramic radiographs and DEXA. The visual analysis was done based on the radiographic appearance of the lower border of the mandible on the left side by two observers who were blinded about DEXA results. Intra/Inter-observer variability was ruled out by repeated analysis followed by comparison of different grades of MCI (Mandibular Cortical Index) and BMD (Bone Mineral density) statistically. Significant difference in three groups of mandibular cortical index of panoramic radiograph as interpreted by the two observers (p value < 0.05) was found .The intra-observer reproducibility of this index had moderate agreement (Kappa value of 0.35 & 0.31) and the inter-observer agreement of this index followed fair reproducibility (kappa value of 0.38 &0.32). It was concluded that there is a significant correlation between results obtained by mandibular cortical index (MCI) and bone mineral density (BMD) of the lumbar vertebrae as determined by the dual energy x-ray absorptiometry implicating visual assessment of the OPG as an important screening tool for osteoporosis in postmenopausal females.

Keywords: Mandibular cortical index, bone mineral density, orthopantomogram, DEXA**Correspondence:**

Dr. Puja Chauhan, Department of Anatomy , Shri Guru Ram Rai Institute of Medical and Health Sciences, Patel Nagar, Dehradun, 248001 Uttarakhand, India. Tel: +91-955775 Fax: 0135-2522117 E-mail: drpujachauhan@gmail.com

Date of submission: 24 Jan, 2014

Date of acceptance: 11 Apr, 2014

Introduction

Prevention and early diagnosis is crucial not only in conditions which are incurable but also in conditions which are difficult to treat once they progress. One of such conditions is osteoporosis. It results in low bone mineral density and disrupted bone tissue microstructure leading to increased bone fragility and fracture risk. It is estimated that 1 in 3 women and 1 in 12 men over the age of 50 worldwide have osteoporosis (1). 40% and 15-30% of osteoporotic

women and men respectively end up having fragility fractures in their lifetime (2).

The gold standard for determining osteoporosis is DEXA (Dual Energy X-ray Absorptiometry). But high cost and unavailability of this equipment at many diagnostic centers limits its usefulness for screening examination. Panoramic radiographs/ (OPG) widely used for dental examination to detect and scrutinize dental diseases can be a very cost effective method for screening osteoporosis. The use of these radiographs for

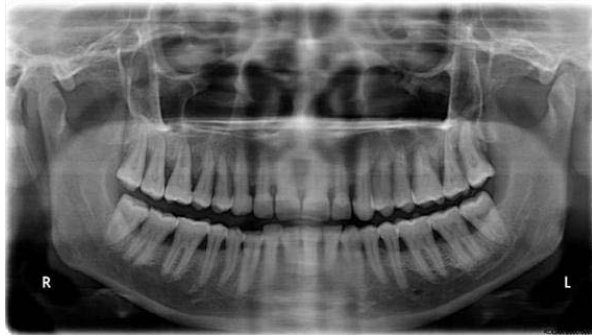


Figure 1: OPG showing normal mandibular cortex (C1)

assessing individuals with low skeletal bone mineral density would be very economical and beneficial as the dentists can refer the patient for further examination if required.

Materials and Methods

Female subjects with in age group of 50 to 72 years reporting to the Dental Department of SGRRIM & HS, Dehradun, India whose post-menopausal status of at least one year was confirmed by detailed history were included in this study. Proper written consent was taken by all of them. Ethical approval was not required for this study. Patients were subjected to digital panoramic radiographic examination followed by DEXA for estimation of bone mineral density of the lumbar vertebrae (L2-L4). The lumbar spine was taken for comparison with panoramic radiograph as the spine and femur is considered as the gold standard for diagnosis of osteoporosis.

All the radiographs were analyzed by using the criteria proposed by Klemetti et al. by two separate observers who were blinded about the dual energy x-ray absorptiometry results (3). The analysis was repeated by both the observers after one month. The visual analysis was done by radiographic appearance of the lower border of the mandible near the mental foramen of the left side in panoramic radiographs which is based on MCI. The MCI at lower border of mandible in panoramic radiograph is basically a three point index (C1-3) and was assessed using the following criteria.

- C1: even and sharp endosteal margin of the cortex (Fig 1)
- C2: Bilateral presence of semilunar defects (lacunar resorption) /endosteal cortical residues (one to three layers) (Fig 2)
- C3: Bilateral presence of porosity and cortical residual in endosteum.(Fig 3)

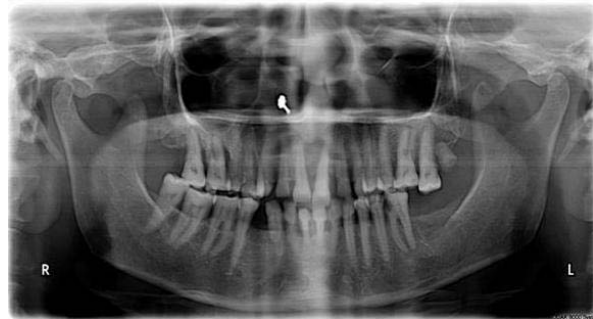

Figure 2: OPG showing mildly eroded mandibular cortex (C2)

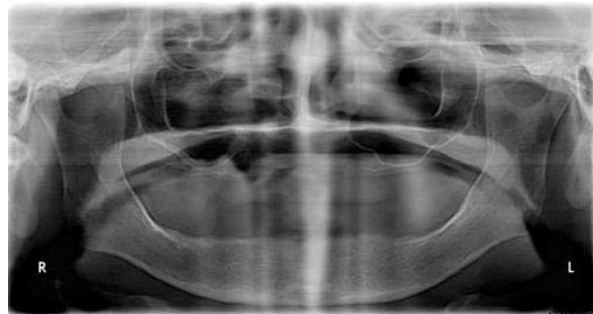


Figure 3: OPG showing severely eroded mandibular cortex (C3)

The results were tabulated and analyzed to assess the relation between the MCI of panoramic radiograph and the bone mineral density obtained from DEXA of L2 to L4 region. Intraobserver and interobserver agreement for the classifications in MCI was also calculated.

The correlation between the different grades of the MCI of orthopantomograph and bone mineral density obtained from DEXA was compared. Spearman's Rank Correlation coefficient was used to find the association between the different grades of MCI and BMD. The intra-observer and inter-observer reproducibility was calculated by using Cohen Kappa Statistics.

- Less than 0.00 – poor
- 0.00 to 0.20 – slightly
- 0.21 to 0.40 – fair

Results

The present study has compared between the bone mineral density (BMD) obtained by DEXA and the mandibular cortical index of the panoramic radiograph for which the intraobserver and the interobserver reproducibility in the assessment of the grading of the mandibular cortical index have been assessed.

The T score obtained from DEXA showed that 20 patients had normal BMD, 18 had osteopenia and 12 patients were osteoporotic (Fig 4, Table 1). Bone Mineral Density in each of the three groups according to the panoramic index is calculated and the classification is based on the observation made by two observers who were blinded about DEXA results.

Bone mineral density of the subjects in the C3 group was minimum followed by the C2 and C1 groups respectively. Significant difference was observed between the bone mineral densities of the three groups (p value <0.05) as graded by the first observer. BMD according to the second observer showed that there is a progressive decline in the mean BMD values from C1 to C3 groups. It was also observed that there was a significant difference (p value <0.05) in the values of the BMD between the three groups.

The intraobserver reproducibility of MCI as assessed by the first observer and second observer had fair agreement (Kappa value was 0.35 and .31 resp). The interobserver agreement for the visual analysis of the lower border of mandible as seen in the panoramic radiograph in the first and observation showed fair agreement with the Kappa value of 0.38 and 0.32 respectively.

Spearman’s Rank correlation coefficient was calculated between the various grades according to the classification of mandibular cortical index and bone mineral density. The value was found to be significantly in correlation with both first observer and second observer (p <0.05) (Table2).

The correlation between different grades of OPG as graded by the first observer and individual T score of the DEXA analysis was also calculated (Table 3). The kappa value was found to be 0.492 which showed moderate agreement.

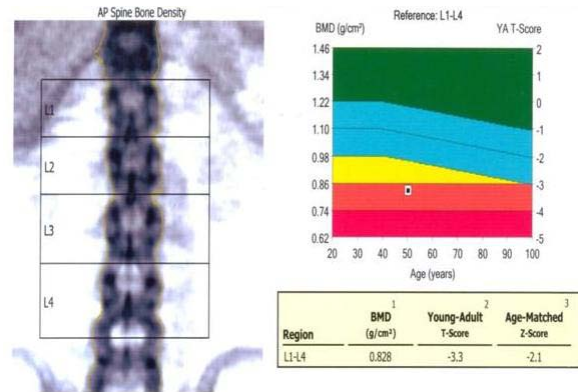


Figure 4: Dexa analysis showing t score with BMD

Table 1: Bone Mineral Density by DEXA

DEXA Diagnosis	N	BMD	SD	Range
Normal	20	1.179	0.218	0.783-1.487
Osteopenia	18	.971	0.017	0.989-1.074
Osteoporosis	12	.762	0.079	0.814-0.974

Table 2: Spearmans rank Correlation coefficient between Mandibular cortical index and BMD

	1 st observer		2 nd observer	
	Spearmans correlation coefficient	Probability	Spearmans correlation coefficient	Probability
1 st observation	-0.477	p <0.05	-0.312	p <0.05
2 nd observation	-0.433	p <0.05	-0.157	p <0.05

Table 3: Co-relation between OPG Index of 1st observer and T- Score of DEXA

OPG Grades	DEXA Diagnosis			Total
	Normal	Osteopenia	Osteoporosis	
C1	13	2	0	15
C2	7	13	3	23
C3	0	3	9	12

Table 4: Co-relation between OPG Index of 2nd observer and T- Score of DEXA

OPG Grades	DEXA Diagnosis			Total
	Normal	Osteopenia	Osteoporosis	
C1	14	4	0	18
C2	6	12	2	20
C3	0	2	10	12

The correlation between different grades of OPG as graded by the second observer and individual T score of the DEXA analysis was also calculated (Table 4).

The kappa value was found to be 0.54 which showed moderate agreement.

Discussion

Osteoporosis is a skeletal disorder resulting from systemic disturbances which implicates low bone mass and micro architectural deterioration of the bone scaffold turning the bone fragile and susceptible to recurrent fractures (1). Inability of the body to form enough new bone or too much of re-absorption of old bone results in an imbalance between the two, leading to osteoporosis. Calcium and Phosphate are the two essential minerals involved in remodeling of bones. Calcium is required for proper functioning of vital organs which is made available in adequate amount by its resorption from bones. Inadequate calcium intake or defective absorption of calcium from the diet, leads to inadequate bone tissue and defective bone formation (3). Early screening and diagnosis of osteoporosis can save many lives.

Panoramic radiograph is widely used for dental examination as it is easily available and cost effective as compared to the other advanced imaging modalities. Indices using panoramic radiographs have been proposed as an indicator of the bone mineral density (4,5). Radio morphometric index is based on the morphological or visual analysis of the panoramic radiograph (6,7). Klemetti et al. had proposed a radio morphometric index based on the visual appearance of the lower border of mandible (3). This was called as Mandibular cortical index.

The present study evaluated the relation between this index and the BMD of the lumbar spine region. Many studies have proved this innumerable time that DEXA of the lumbar and hip region are gold standard for diagnosing osteoporosis. This is the reason for taking BMD from DEXA as the parameter for correlation

with different grades of MCI. Few studies have tried correlating m-DEXA (mandibular DEXA with panoramic indices but the reliability of m-Dexa has not yet been proved. Cakur et al. in one of their studies tried to correlate between MCI and m-DEXA and found no significant correlation between the two (8). Another study by Horner and Devlin has also calculated mean BMD using m-DEXA (9). Because of the disparity in the results obtained serious uncertainties have been raised about the genuineness of m-DEXA. Hence the present study utilizes DEXA of lumbar spine for determination of BMD.

There is a high risk of osteoporosis associated with the post-menopausal females because of which the present study was done on female subjects (6,10). In the present study 40% patients had normal BMD and the rest 60% of patients had reduced BMD (Table 1). This is consistent with other studies that also showed the irrefutable evidence of higher incidence of osteoporosis associated with elderly patients (11).

In the present study panoramic radiographs of all the subjects were interpreted according to the mandibular cortical index (MCI) by two observers who were blinded about the DEXA results. The bone mineral density in each group was assessed. It was found that there was statistically significant difference in the bone mineral density of three groups (p value <0.05) as interpreted by the first observer and second observer. The mean BMD value of C1 was highest followed by C2 and least in C3 as interpreted by both the observers in the present study. Thus it confirms that patients with C2 and C3 type of mandibular cortex are more prone for fracture due to osteoporotic changes.

Inter-observer agreement was also calculated in the present study. The inter-observer agreement in the first observation was found to be 0.38 and in the second observation was found to be 0.32. Both the observations show fair agreement. Another study done by Lee et al. to assess the relation between mandibular cortex on OPG and BMD reported intra-observer agreement almost perfect (Kappa score .89,.92) for the

first and second for the second it was substantial (.77) (12).

Variation in the inter-observer agreement between the present study and the above mentioned study can be attributed to small sample size in the present study.

In the present study values between the various groups according to the classification of mandibular cortical index and bone mineral density showed significant correlation for the first observer & second observer (p value <0.05).

The correlation between different grades of OPG and individual T score of the DEXA as observed by the first and second observer. (Table 3, 4) was found to have moderate agreement (k value 0.492, 0.54).

Hence the present study shows that mandibular cortical index i.e. a simple three graded classification of radiographic changes in the lower border of mandible can be used to distinguish normal subjects & subjects with altered bone mineral density.

Thus, postmenopausal females with significant thinning of mandibular cortex should be referred for further evaluation of osteoporosis by the dentists. Therefore visual estimation of the panoramic radiograph can be used as a screening procedure for diagnosis and referral of patients for further evaluation of osteoporosis.

Conclusion

Osteoporosis is a systemic disorder that also affects the jaw bones and OPG being an affordable, easily available alternative, this study was undertaken to assess its efficacy as an effective tool for screening of osteoporosis. After subjecting all the patients to DEXA and OPG, followed by statistical analysis of the results, the study concluded that there is a significant correlation between mandibular cortical index (MCI) and bone mineral density (BMD) of the lumbar vertebrae as determined by the dual energy x-ray absorptiometry (DEXA). The intra-observer reproducibility of this index has moderate agreement and the inter-observer agreement of this index follows fair reproducibility. Therefore, visual examination of the panoramic radiographs can be used as an effective screening procedure for diagnosis and referral of patients for further evaluation of osteoporosis. Hence dental professional should be trained to interpret radiographs accurately as assessment of lower border of mandible is a key for early diagnosis of osteoporosis which is a burning issue today. However, further studies should be carried out in larger population to substantiate the results.

References

1. White SC. Oral Radiographic predictors of osteoporosis. *Dentomaxillofac Radiol* 2002; 31(2): 84-92.
2. Melton LJ. How many women have osteoporosis now? *J Bone Miner Res* 1995; 10(2): 175-7.
3. Klemetti E, Kolmakov S, Kroger H. Pantomography in assessment of the osteoporosis risk group. *Scand J Dent Res* 1994; 102(1): 68-72.
4. Leite AF, Figueiredo PT, Guia CM, Melo NS, de Paula AP. Correlation between seven panoramic radiomorphometric indices and bone mineral density in postmenopausal women. *Oral Surg Oral Med Oral Pathol Oral Radiol Endod* 2010; 109(3): 449-56.
5. Edwards BJ, Migliorati CA. Osteoporosis and its implications for dental patients. *J Am Dent Assoc* 2008; 139(5): 545-52.
6. Ishii K, Taguchi A, Nakamoto T, et al. Diagnostic efficacy of alveolar bone loss of the mandible for identifying postmenopausal women with femoral osteoporosis. *Dentomaxillofac Radiol* 2007; 36(1): 28-33.
7. Dutra V, Yang J, Devlin H, Susin C. Radiomorphometric indices and their relation to gender, age and dental status. *Oral Surg Oral Med Oral Pathol Oral Radiol Endod* 2005; 99(4): 479-84.
8. Cakur B, Dagistan S, Sachin A, Hororli A, Yilmaz A. Reliability of mandibular cortical index and mandibular bone mineral density in the detection of osteoporotic woman. *Dentomaxillofac Radiol* 2009; 38(5): 255-61.
9. Horner K, Devlin H. The relationship between two indices of mandibular bone quality and bone mineral density measured by dual energy x-ray absorptiometry. *Dentomaxillofac radiol* 1998; 27(1): 17-21.
10. Nagler RM, Hershkovich O. Relationships between age, drugs, oral sensorial complaints and salivary profile. *Arch Oral Biol* 2005; 50(1): 7-16.
11. Taguchi A, Tanimoto K, Sueti Y, Otani K, Wada T. Oral signs as indicators of possible osteoporosis in elderly women. *Oral Surg Oral*

Med Oral Pathol Oral Radiol Endod 1995; 80(5): 612-6.

12. Lee K, Taguch A, Ishii K, et al. Visual assessment of the mandibular cortex on

panoramic radiographs to identify postmenopausal women with low bone mineral densities. Oral Surg Oral Med Oral Pathol Oral Radiol Endod 2005; 100(2): 226-31.