

Case Report

Hara-Kiri through Anal Orifice: A First-of-Its-Kind Case

Harsh D¹ (✉), Jagdeep R², Rajendra M¹

¹Department of General Surgery, ²Department of Plastic Surgery, Sawai Man Singh Medical College, Jaipur, Rajasthan-302004, India.

Abstract

Constipation and obstruction are distressing problems which not promptly treated can lead to dangerous complications. A common and potentially dangerous gastrointestinal problem is faecal impaction. Early diagnosis and prompt treatment avoids complications. Apart from manual extraction proximal and distal washout are the available options. However, the key lies in identifying the etiology of the problems and nipping it in the bud. We here present a first-of-its-kind case in which a female pulled out about 2 feet of her large intestine from her anal orifice after experiencing constipation for a period of two days. Damage control surgery was done and the patient was left with a permanent ileostomy.

Keywords: Abdominal distension, air fluid levels, emergency laparotomy, gangrenous bowel, volvulus

Correspondence:

Dr. Harsh Deora, Department of General Surgery, Sawai Man Singh Medical College, Jaipur, Rajasthan-302004, India. Tel: 9610407805 Fax: 07512459946 Email: demo5601@gmail.com

Date of submission: 11 Apr, 2013

Date of acceptance: 01 Aug, 2013

Introduction

Hara-kiri or Seppuku ("stomach-cutting") is a form of Japanese ritual suicide by disembowelment. During this ceremony a short blade is traditionally plunged into the abdomen and the blade is moved from left to right in a single, smooth slicing motion and it is usually performed in front of spectators with elaborate rituals (1). A common and potentially dangerous gastrointestinal problem is faecal impaction (2). Faecal impaction remains an overlooked condition, despite a multimillion dollar laxative industry in our bowel conscious society, especially in the elderly where it dramatically impairs the quality of life (3) Read and colleagues found that as many as 42% of patients in a Geriatric ward have faecal impaction (4). We here present a case with obstruction who presented with the most dramatic complication possible.

Case Report

A 30-year-old woman presented to the casualty with profuse bleeding per rectally and carrying with her about two feet of intestine in a jar which was pulled

out by her from her anal orifice. After necessary resuscitation for her shock, which included fluid administration, vasopressors and rectal packing, a detailed history was obtained. She complained of feeling constipated for the past two days which was not relieved with medication. When she tried to manually dislodge the stools, she felt a mass in the anal orifice. On pulling out the mass, about two feet of intestine got pulled out.

The patient was then immediately shifted to the emergency operating room. The on-table examination showed a large perineal tear present at 2 and 6 o'clock with multiple small tears all around the circumference of anal orifice (Fig.1). Fresh bleeding was present. No anal sphincter or anal tone was present. Entire fist could be admitted through the anal orifice into what appeared to be the pelvic cavity. Perineal muscles were torn and bleeding. Per-vaginally, however, no bleeding or tear or fistula could be discerned.

An immediate laparotomy was planned after taking temporary & permanent ileostomy consent. About 500ml of fresh blood mixed with faecal matter was

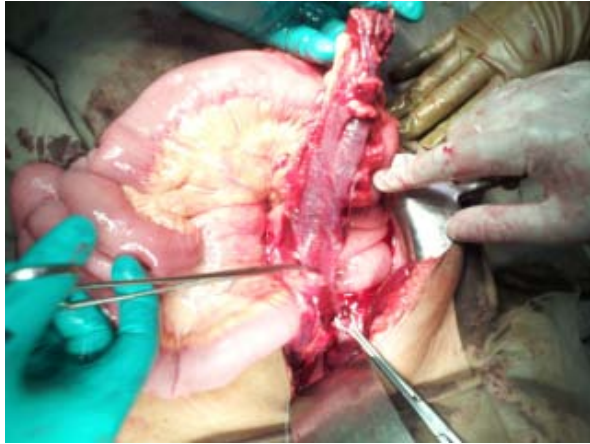


Figure 1: Laprotomy picture showing the gangrenous colon on the right and the viable small intestine on the left. Note also that there is no mesenteric tear present on the small intestine.

present in pelvic cavity. Half of the circumference of the antimesenteric border of the intestine from the rectosigmoid junction up to ascending colon-caecum junction was absent. Rest of the small intestine along with its mesentery was intact with a hematoma on the caecum (Fig.2). A total proctocolectomy along with a permanent end ileostomy with layer by layer repair of the perianal tear was performed. The patient was later weaned off vasopressors on her 2nd post operative day. A psychiatric evaluation was done as soon as her condition permitted. The Psychiatrist, however, did not find any abnormality in his examination. With the ileostomy working she was discharged on the 10th post-operative day. She continues to be well at six month follow-up.

Discussion

Even after extensive search no similar cases have been reported, in literature. The possible mechanism could have been a serosal tear as has been seen in trauma by penetrating injuries (5).

There are many causes for fecal impaction including inadequate fiber and hydration, spinal cord injury, aging. Drugs causing impaired gastrointestinal motility include opiate analgesics, anticholinergic agents, calcium channel blockers, antacids, and iron preparations (3). Laxative abuse, paradoxically, is associated with constipation and faecal impaction. The affected individual is unable to produce a normal response to the distention of colon and progressively needs higher doses for achieving a bowel movement (6). Apart from pharmacological causes, congenital and acquired conditions of the colon, including

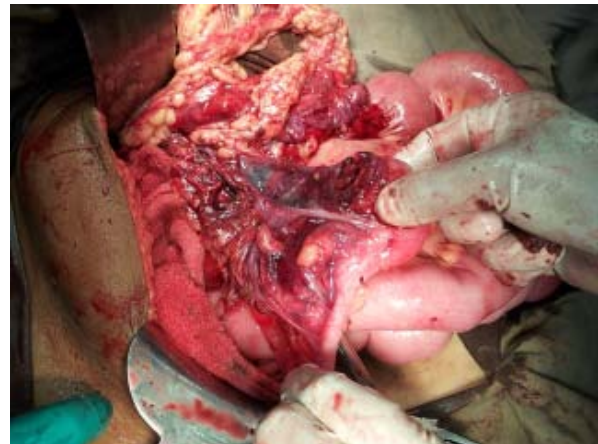

Figure 2: The cut end of gangrenous colon showing hematoma at the caecum.

Hirschsprung's disease and Chagas' disease, may lead to fecal impaction (7). There is also a need to exclude other anatomic and functional abnormalities of the anorectum apart from the above etiologies (8).

Manual fragmentation of the hardened stool if found to be palpable in the rectum is required. A lubricated, gloved index finger is inserted into the rectum and using a scissoring motion, the stool is fragmented. Circular movement of the finger is performed to ensure disimpaction of the faecoliths. These faecoliths are then removed by bending the finger and extracting the stool with it. This process may be repeated until the rectum is clear of the hardened stool. An anal retractor (i.e., Hill-Ferguson retractor) may aid in manual disimpaction (9).

Our case is unique, in that the patient was a young female with none of the above mentioned risk factors. No psychiatric abnormality was found and she continues to be in regular follow-up without any complaints apart from those arising due to the stoma.

Such injuries are uncommon and thus their management as learnt from the above case depends on rapid and effective resuscitation and damage control surgery. Management should also focus on attending the co-morbidities and long term rehabilitation of these permanently scarred individuals.

References

1. Fusé, Toyomasa. Suicide and culture in Japan: A study of seppuku as an institutionalized form of suicide. *Soc Psychiatry Psychiatr Epidemiol* 1979;15(2): 57-63.

2. Tracey J. Fecal impaction: not always a benign condition. *J Clin Gastroenterol* 2000; 30(3): 228–229.
3. De Lillo AR, Rose S. Functional bowel disorders in the geriatric patient: constipation, fecal impaction, and fecal incontinence. *Am J Gastroenterol* 2000; 95(4): 901–905.
4. Read NW, Abouzekry L, Read MG, Howell P, Ottewell D, Donnelly TC. Anorectal function in elderly patients with fecal impaction. *Gastroenterology* 1985; 89(5): 959–966.
5. Townsend CM, Beauchamp RD, Evers BM, Mattox KL. (eds). *Sabiston Textbook of Surgery: the biological basis of modern surgical practice* 19th Edn. New York: Elsevier Saunders, 2012, pp-435.
6. Reichel W. *The Geriatric Patient*. New York: HP Publishing Co, 1978, pp-78.
7. Wrenn K. Fecal impaction. *N Engl J Med* 1989; 321(10): 658–662.
8. Youssef NN, Peters JM, Henderson W, Shultz-Peters S, Lockhart DK, Di Lorenzo C. Dose response of PEG 3350 for the treatment of childhood fecal impaction. *J Pediatr* 2002; 141(3): 410–414.
9. Beck DE. Fecal impaction. *Tech Gastrointest Endosc* 2004; 6: 41–43.