

Case Report

Synergistic Typhoid and Taenia Solium Intestinal Perforation

Ashwani K (✉), Pankaj KG, Divya S, Paras KP, Vijay KS

Department of Surgery, Rajindra Hospital and Government Medical College, Patiala, Punjab, 147001 India.

Abstract

Typhoid and intestinal infestation with parasites are common and may co-exist especially in the tropics. Their synergistic acute abdominal presentation is rare. We here report a 38-year-old male who presented with complaints suggestive of enteric fever and signs of peritonitis. Following baseline investigations, laparotomy was performed which proved to be a surgical surprise. A live tape worm was seen pouting out of the terminal ileal perforation. The clinical presentation and the stringent attention to preventive measures are discussed.

Keywords: Acute abdomen, Taenia solium, Salmonella typhii, tropics, perforation

Correspondence:

Ashwani Kumar, Department of Surgery, Rajindra Hospital and Government Medical College, Patiala, Punjab, 147001 India. Tel: +919815504819 Fax: 01752212542 Email: ashwanicmc@hotmail.com.

Date of submission: 10 Nov, 2012

Date of acceptance: 19 Feb, 2013

Introduction

Small bowel perforations due to helminthic infestations are mainly caused by *Ascaris lumbricoides* (1). Ascariasis and typhoid (*Salmonella typhii*) septicemia remain highly prevalent diseases in the tropics, with poor hygienic and low socioeconomic conditions being the main incriminated factors (2). Both diseases are renowned for causing acute ileal perforation. On the other hand both diseases may co-exist (3). Synergistic typhoid and ascarid intestinal perforation has been reported by Okeniyi et al (4).

Taenia Solium is an exceptional cause of small intestinal perforation and is probably under-reported. A review of the relevant literature did not reveal any case of synergistic typhoid and *Taenia Solium* intestinal perforation.

Case Report

A 38-year-old vegetable vendor, chronic alcoholic for the past 15 years, presented to the emergency with complaints of pain abdomen, vomiting, abdominal distention and constipation for the past 2 days. After

conducting routine blood and urine investigations, an erect chest x-ray was performed. It revealed free air under both domes of the diaphragm. An exploratory laparotomy was performed and the intra-operative findings were as follows: (I) Single perforation present in the ileum, about 20 cm proximal to the ileo-caecal junction, measuring 2x2 cm in size, on the anti-mesenteric border. (II) Two ribbon shaped segmented tape-worms, each measuring about 3 m in length, protruding out from the perforation site (Fig.1)

The tape-worms were removed and the perforation site was closed in a single layer (Fig.2). Post-operatively, the patient was administered broad spectrum antibiotics and anti-helminthic therapy was instituted. His preoperative blood culture was positive for *Salmonella typhii*. The histology of perforation margin showed oedema and invasion of the lamina propria by polymorphonuclear leukocytes. On retrospective interrogation, the patient gave history of eating undercooked and partially cooked meat regularly. He also gave history of passing worm-like structures in his stool for the past one year. His further stay in the hospital was uneventful, and he was discharged in a satisfactory condition.

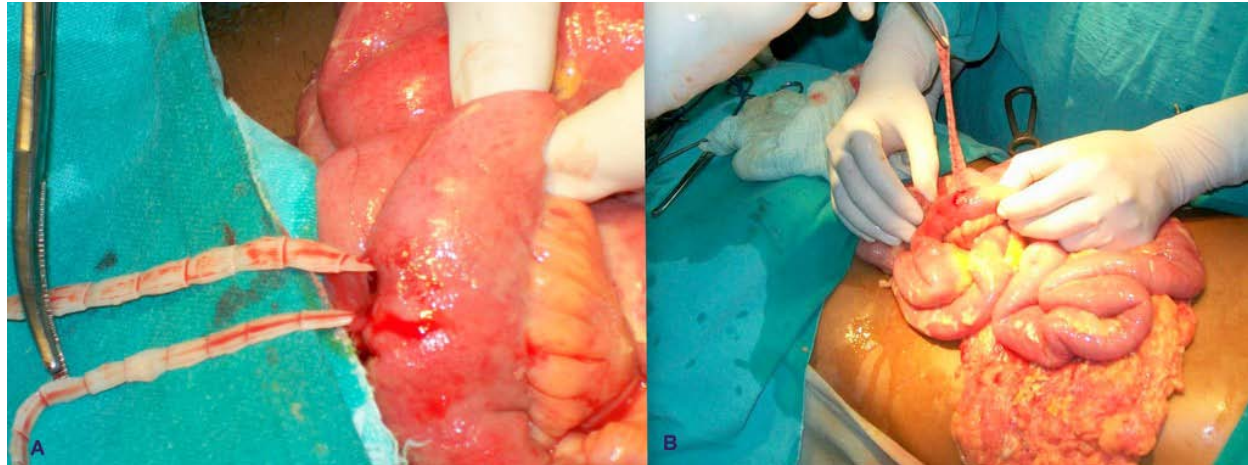


Figure 1: A) Tape-worm coming out from red edematous ileum. B) Tape-worm being extracted from perforation site with forceps.

Discussion

Small bowel perforations due to helmenthic infestations are mainly caused by *Ascaris lumbricoides* (1). *Taenia* is an exceptional cause of small intestinal perforation. The presentation of patients with a small bowel perforation caused by *Taenia* cannot be distinguished from many other causes of acute surgical emergencies (5). The incidental presence of tape-worms in the bowel lumen contributes considerably to the bowel perforation. In doubtful cases a diagnostic laparotomy should be performed (6).

Synergistic Typhoid and Taeniasis can cause several surgical complications with high morbidity and mortality as prevalence of taeniasis is high especially in tropical zones. The mortality rate due to small intestinal perforation associated with infestation, which is mostly related to primary disease, may reach upto 42% (7).

The macroscopic picture of the small bowel perforation in our case could not be distinguished from other common causes of perforation such as typhoid fever, which undoubtedly represents the most common cause of small bowel perforation worldwide (8). Supportive evidence of this synergy between typhoid and tape worm infestation are the short duration of illness and positive blood culture sent preoperatively for *Salmonella typhi*. Synergistic Typhoid and Taeniasis perforation probably follows ischemia from pressure by the mass of worms in the small intestine (9). *Taenia Solium* may worsen typhoid enteritis by converting imminent to real perforations. Synergistic taenia infestation may lead to earlier intestinal perforation and accelerated clinical presentation in typhoid enteritis. These two tropical diseases affecting

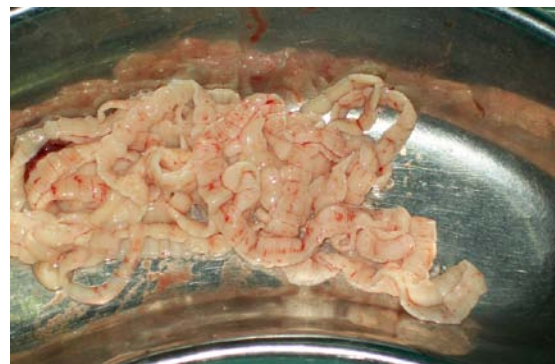

Figure 2: The tape-worm after extraction from the ileum.

the small bowel are predominantly preventable. It is interesting to note that there are some part of the developing world where the number of typhoid enteric perforation and ascariasis are still increasing day by day in spite of worldwide improvement in public awareness of hygiene and good sanitation. *Salmonella* vaccination may therefore be incorporated into the National Programme of Immunisation for children at risk of typhoid enteritis (10). These efforts should be complemented by mass anti-helminthic chemoprophylaxis which may further help ameliorate the risk of early intestinal perforation occurring in children with helminthiasis coexisting with typhoid enteritis (4).

Conclusion

Synergistic typhoid and *Taenia Solium* bowel perforation is a rare entity and has not been reported in the literature so far. These two diseases of small bowel are preventable by means of salmonella vaccination and antihelminthic chemoprophylaxis and improvement in personal hygiene and sanitation.

References

1. Curbelo AL, Galan CR. Intestinal perforation by *Ascaris lumbricoides*. *Rev Cubana Med Trop* 1980;32(2):165-7.
2. Okeniyi J, Ogunlesi T, Oyelami O, Oyedeji G. Asymptomatic intestinal parasitosis among semi-urban Nigerian children. *Internet Epidemiol* 2005; 2(2)
3. Ajao OG. Typhoid perforation: factors affecting mortality and morbidity. *Int Surg* 1982; 67(4):317-9.
4. Okeniyi JAO, Lawal OA, Dedeke IOF, Agbakwuru EA. Synergistic Typhoid and Ascarid Intestinal Perforation. *Nigerian Medical Practitioner* 2007; 52(5): 109-111.
5. Demiriz M, Gunhan O, Celasun B, Aydin E, Finci R. Colonic perforation caused by taeniasis. *Trop Geogr Med* 1995; 47:180-182.
6. Angiò LG, Rivoli G, Bagnato U, Campolo V, Piazzese E, Travagliante M. Blunt hernia trauma with ileal perforation and incidental finding of *Taenia saginata* infestation. *Chir Ital* 2000;52(5):603-9.
7. Buzio M, Shoshtari Mahmoud K, Memore L, Cotogni P. Perforation of the small intestine. *Minerva Chir* 1999;54(12):851-4.
8. Dawson JH. Surgical management of typhoid perforation of the ileum. *Am Surg* 1970;36(10):620-2.
9. Wani NA, Shah OJ, Wani MA. Surgical complications of abdominal ascariasis. *Postgraduate Doctor Africa* 2002; 24: 38-40.
10. Centers for Disease Control and Prevention. Recommendation of Advisory Committee on Immunization Practices (ACIP): Typhoid immunization. *MMWR* 1994; 43 (RR-14): 1.