

## Case Report

# Bilateral Ossified Pterygospinous Ligament and Its Clinical Significance

Raju S (✉)<sup>1</sup>, Sujatha M<sup>1</sup>, Indira Devi B<sup>1</sup>, Sirisha B<sup>1</sup>, Sri Devi P<sup>2</sup>

<sup>1</sup>Department of Anatomy, RIMS Medical College, Rajiv Gandhi Institute of Medical Sciences, Kadapa-516002. A.P. India.

<sup>2</sup>Department of Anatomy, RIMS Medical College, Rajiv Gandhi Institute of Medical Sciences, Srikakulam. A.P. India.

### Abstract

The ossification of the pterygospinous ligament form the bridge known as pterygospinous bony bridge and it may create a pterygospinous foramen. Close location of this ossified pterygospinous ligament to the foramina ovale, can entrap the mandibular nerve and its branches which emerges through the foramen ovale and may produce the clinical condition known as mandibular neuralgia. Presence of such ossified pterygospinous ligament may also interfere with the mandibular nerve block. Here, we report a rare case of ossified pterygospinous ligament bilaterally in a dried adult skull. The measurements of variant pterygospinous foramen were recorded as 4.25 mm horizontally and 4.55 mm vertically, on the right side and 4mm, 4.10 mm on the left side. This variation is clinically important for Surgeons, Neurologists and Anesthetists.

**Keywords:** Pterygospinous ligament, mandibular neuralgia, pterygospinous foramen, foramina ovale, ossification

### Correspondence:

Raju Sugavasi, Department of Anatomy, RIMS Medical College, Rajiv Gandhi Institute of Medical sciences, Kadapa- 516002. A.P. India. Tel no: +91-9849501978 Email: anatraju@yahoo.co.in

Date of submission: 12 June, 2012

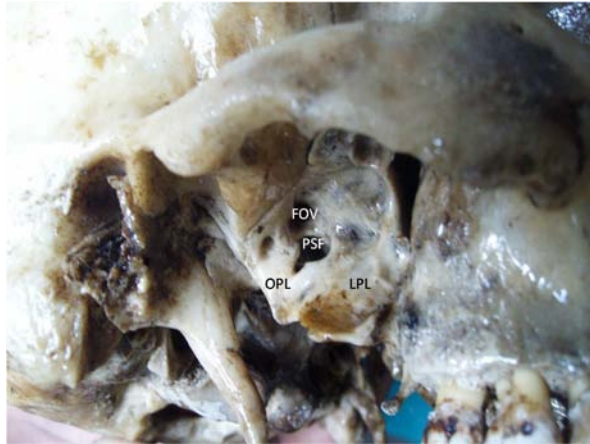Date of acceptance: 25 Aug, 2012

### Introduction

The pterygospinous ligament extends from the lateral plate of pterygoid process of sphenoid bone to the spine of sphenoid. pterygospinous ligament occasionally replaced by muscle fibres which extends between spine of sphenoid and posterior border of lateral pterygoid bone (1). This may sometimes ossified, this can convert into an incomplete or complete ossified bony bar or a foramen. Mandibular nerve branches may passes through this foramen and may get compressed which may leads to clinical conditions like mandibular neuralgia, lingual numbness. Civinini cited by Tebo, 1968 (2) described the pterygospinous ligament this connection was going from the spine of the sphenoid bone to the pterygospinous process that forms the pterygospinous foramen.

### Case Report

During routine osteology teaching classes for undergraduate medical students in the department of anatomy we noticed a case of ossified pterygospinous ligament both right (Fig. 1) and left side (Fig. 2) of dried adult skull. A bony bar was arising from the posterior border of lateral pterygoid plate of pterygoid process to the spine of sphenoid bone both sides. This bony bar was thick and consisting of an oval foramen which is related inferior to the foramina ovale. The diameters of variant pterygospinous foramen were 4.25 mm horizontally and 4.55 mm vertically on right side and 4 mm, 4.10 mm on left side. In the present variation the author observed the complete ossified pterygospinous ligament bilaterally.

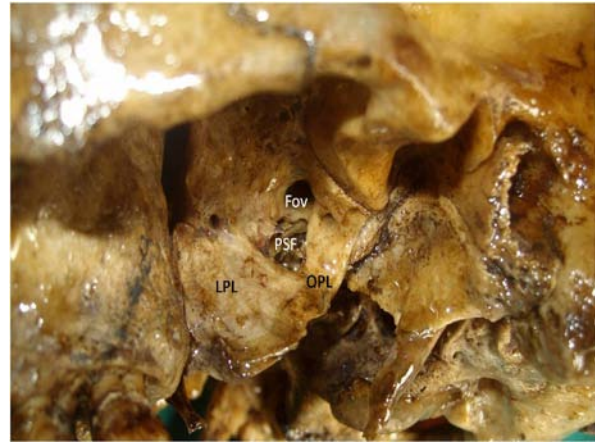


**Figure 1:** Showing the Right side complete ossified pterygospinous ligament. PSF-Pterygospinous Foramen; OPL-Ossified Pterygospinous Ligament; LPL-Lateral Pterygoid Lamina, FOV-Foramen ovale.

### Discussion

The ossification of pterygospinous and pterygoalar ligaments were defined and examined by many previous researchers and also pterygospinous bony bridges incidence were reported by different authors with different results. According to Pinar et al. (3) Out of 361 dried adult skulls 12 samples of complete ossified pterygospinous ligaments and 35 samples of incomplete ossified ligaments were observed and also complete ossified pterygoalar ligaments in four samples and incomplete ossified ligaments in 18 samples were observed. Krmpotic et al. (4) observed five ossified pterygospinous ligaments out of 100 skulls. According to Nayak et al. (5) out of 416 dry human skulls 9.61 % of incomplete pterygospinous bony bar, 3.84 % of incomplete pterygospinous foramen and 5.76 % of complete pterygospinous bony bar and foramen were observed. Von Ludinghausen et al. (6) reported the complete pterygospinous bony bar as 1.85 % on cadaver and as 6% on dried skulls. Only a few cases of bilateral complete pterygospinous ligaments were reported yet. Patnaik et al. (7) reported a single case of complete bilateral pterygoalar bar in a dried skull. Suazo et al. (8) conducted a study on 116 skulls and observed 5.12% of type 2, 1.28% of type 3 and 7.69% of type 4 of bilateral ossified pterygoalar bars. So the present variation is important because bilateral occurrence of this very rare.

Many researchers were explained regarding the importance and clinical significance of ossified pterygospinous and pterygoalar ligaments. According to Newton and Potts (9) these ossified ligaments can



**Figure 2:** Showing the Left side complete ossified pterygospinous ligament. PSF-Pterygospinous Foramen; OPL-Ossified Pterygospinous Ligament; LPL-Lateral Pterygoid Lamina, FOV-Foramen ovale.

be an obstruction in a radio graphically guided trigeminal ganglion blockage. Kapur et al. (10) reported that pterygospinous and pterygoalar bony bridges can be 3 to 3.5 cm in depth and may prevent the anesthesia of mandibular nerve at the lateral sub zygomatic approach. According to Das and Paul (11), the pterygospinous and pterygoalar bony bridges have got the great clinical significance to the anesthetic treatment of the mandibular nerve and for therapeutics for the trigeminal ganglion, because their presence may hamper the access to the needle in the vicinity of the oval foramen. The anatomical knowledge of this ossified bridges and their prevalence is important for Surgeons, neurologists and anesthetists.

### Conclusion

The knowledge of the anatomical variation like ossified pterygospinous ligament is important because it is very rare finding, which can be produces nerve entrapment syndromes. Ossified pterygospinous ligament is important for surgeons and anesthetists because this can interfere with the surgical and anesthetic procedures.

### References

1. Standring Susan. Gray's Anatomy. The Anatomical basis of clinical practice. 39<sup>th</sup> ed. Edinburg: Elsevier Churchill Livingstone. 2005, pp-521.
2. Tebo HG. The pterygospinous bar in panoramic roentgenography. Oral surg. Oral med .oral pathol 1968; 26(5): 654-7.

3. Pinar Y, Arsu G, Aktan Ikiz ZA, Bilge O. The pterygospinous and the pterygoalar bridges. *Sendrom*. 2004;18:66-69.
4. Krmptic-Nemanic J, Vinter I, Hat J, Jalsovec D. Mandibular neuralgia due to anatomical variations. *Eur Arch Otorhinolaryngol* 1999; 256 (4): 205–208.
5. Nayak SR, Saralaya V, Prabhu LV, Pai MM, Vadgaonkar R, D'Costa S. Pterygospinous bar and foramina in Indian skulls: incidence and phylogenetic significance. *Surg Rad Anat* 2007;(29): 5–7.
6. Von Ludinghausen M, Kageyama I, Miura M, Alkhatib M. Morphological peculiarities of the deep infra temporal fossa in advanced age. *Surg Radiol Anat* 2006; 28(3): 284–292.
7. Patnaik VVG, Singla, Rajan K, Bala Sanju. Bilateral Pterygo-Alar Bar and Porus Crotaphitico Buccinatorius –A Case Report. *J Anat Soc India* 2001; 50(2):161-162.
8. Suazo GI, Zavando MD, Smith RL. Anatomical study of the pterygospinous and pterygoalar bony bridges and foramina in dried crania and its clinical relevance. *Int J Morphol* 2010; 28(2):405-408.
9. Newton TH, Potts DG. *Radiology of the skull and brain*. St. Louis, Mosby. 1971; (1) 307.
10. Kapur E, Dilberovic F, Redzepagic S, Berhamovic E. Variation in the lateral plate of the pterygoid process and the lateral sub zygomatic approach to the mandibular nerve. *Med Arh* 2000; 54(3):133–137.
11. Das S, Paul S. Ossified pterygo spinous ligament and its clinical implications. *Bratisl Lek Listy* 2007; 108(3):141-143.