

Case Report

Unusual Branching Pattern of Brachial Artery with Abnormal Superficial Palmar Arch

Srinivasa Rao Bolla¹, Sashi Kumar J¹, Saikat Roy², Narendra Pamidi³, Raghu Jetti (✉)³

¹Department of Anatomy, Mamata Medical College, Khammam, Andhra Pradesh, India

²Department of Anatomy, Kalinga Institute of Medical Sciences, Bhuvaneshwar, Odisha, India

³Department of Anatomy, Melaka Manipal Medical College, Manipal University, Manipal, Karnataka, India

Abstract

Brachial artery is the chief artery of upper limb. Superficial palmar arch plays an important role in most of the traumatic events and the surgical procedures of the hand. The arterial variations of upper limb are useful for vascular surgeons, interventional radiologists, plastic surgeons. The authors report a case of high origin of superficial ulnar artery with abnormal formation of superficial palmar arch.

Keywords: Brachial, artery, upper limb, anomaly, variation, forearm, flaps.

Correspondence:

Raghu Jetti, Department of Anatomy, Melaka Manipal Medical College, Manipal University, Manipal, 476104 Karnataka. Tel: 91-820-2922632, Fax: 91-820-2571905 Email: raghujetti@yahoo.co.in

Date of submission: Jan 28, 2012

Date of acceptance: March 28, 2012

Introduction

Brachial artery is the major artery of upper limb. According to the classical description, the brachial artery is a continuation of axillary artery, at the distal border of teres major. It runs in the anterior compartment of the arm to enter the cubital fossa and ends at the level of neck of radius by dividing into radial and ulnar arteries to supply the forearm and hand (1). The arteria radialis indicis and arteria princeps pollicis are the branches of deep palmar arch. Variations in vascular arrangement of upper limb in the human body have been commonly reported in routine dissections or in clinical studies (2). Knowledge about variations in the arterial pattern of upper limb is essential for successful hand surgeries and vascular grafting, because the superficial palmar arch plays an important role in most of the traumatic events and the surgical procedures of the hand.

Case Report

During regular dissection classes of first year medical students, an upper limb of a formalin fixed male cadaver aged about 60-year-old showed an abnormal branching pattern of brachial artery. The brachial artery began as a continuation of axillary artery at the lower border of teres major. It ran downwards medial to humerus, approximately at the level of insertion of coracobrachialis muscle it gave off an abnormal branch. Rest of the course and branches in the arm was normal. Later the artery passed into cubital fossa and divided into radial artery and common interosseous artery, the normal ulnar artery was absent and it was replaced by the abnormal branch which arose in the arm (Fig. 1).

The abnormal branch was termed as superficial ulnar artery. It ran downwards medial to brachial artery entered cubital fossa. It ran superficial to bicipital

aponeurosis. In the forearm the branch passed downwards superficial to all the flexor muscles and superficial to the flexor retinaculum in the palm. In the palm it ran obliquely across the digital tendons of flexor muscles superficially and lied deep to palmar aponeurosis. In its course it gave origin to one proper palmar digital branch to the ulnar side of little finger and three common palmar digital branches to the adjacent sides of little, ring, middle and ulnar side of index fingers. It terminated by dividing into the radialis indicis artery and arteria princeps pollicis (Fig. 2) at the first interdigital cleft. The superficial palmar arch was completely formed by the superficial ulnar artery; there was no contribution from the radial artery. The counter upper limb of the same cadaver showed normal branching pattern.

Discussion

Brachial artery variations are less common, presence of higher division, high origin of any of the terminal branches, trifurcation and duplication are the reported variations of the brachial artery. William et al mentioned that the brachial artery may bifurcate in the arm; again it may reunite to form a single trunk or it may trifurcate into radial, ulnar and common interosseous arteries (1). Sometimes the ulnar artery alone may arise proximally in the arm. Huber et al found the trifurcation of brachial artery into radial, ulnar and common interosseous or median arteries (2). Patnaik et al reported the trifurcation of brachial artery as radial, ulnar and radial recurrent arteries (3). Bilodi AK et al described the trifurcation of brachial artery into radial, ulnar and common interosseous arteries, bifurcation of brachial artery into radial and ulnar arteries with the origin of common interosseous artery from the radial artery (4).

In our present case this abnormal branch is termed as superficial ulnar artery. Nakatani et al. reported the incidence of superficial ulnar artery 0.6% to 9.4% (5). Cuneyt bozer et al reported the high origin of superficial ulnar artery from the brachial artery in the arm (6). KMR Bhat et al. reported high origin of superficial ulnar artery from brachial artery (7). Rodriguez- niedenfuhr et al. proposed possible embryological explanations of this kind of anomalies. The normal arterial pattern of upper limb is developed by selective enlargement or regression of capillary plexus not from the axial trunk (8). According to Baeza et al. , Singer et al normally there is superficial and deep parts of capillary plexus, due to haemodynamic forces the superficial part of plexus undergo regression deep part of the plexus persist as radial and ulnar arteries. Due to alteration in the haemodynamics sometimes the deep part of the



Figure 1: Showing the high origin of superficial ulnar artery. SUA: Superficial Ulnar artery; BA: Brachial artery; RA: Radial artery; CIA: Common Interosseous Artery.

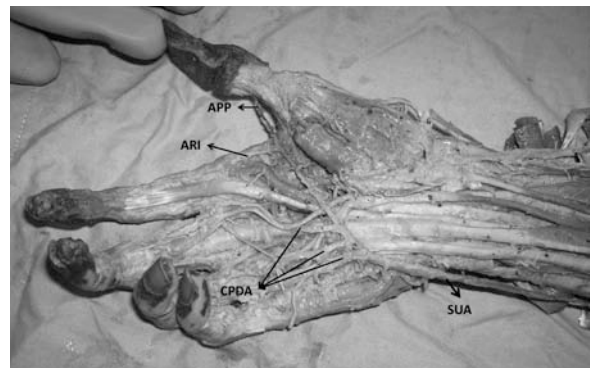


Figure 2: Showing the formation of superficial palmar arch and its branches. SUA: Superficial Ulnar Artery; APP: Arteria Princeps Pollicis; ARI: Arteria Radialis Indicis; CPDA: Common Palmar Digital Arteries.

plexus undergo regression where the superficial part persist as superficial ulnar, superficial radial arteries (9, 10). In our case we found high origin of superficial ulnar artery which formed the entire superficial palmar arch. There is no contribution from the radial artery for formation of superficial palmar arch.

In the present case the superficial ulnar artery was running superficial to all the flexor muscles and is

covered only by the skin and fascia, so that it may be more vulnerable to injuries and results in severe bleeding. It may be mistaken for superficial vein during intra venous drug administration. It may complicate the procedure of brachial artery catheterization. It could be an advantage for the plastic surgeons in the radial forearm flap elevation. Since entire superficial palmar arch is formed by this artery the radial artery can be used for the coronary graft in these subjects without compromising the circulation of the hand.

References

1. Peter LW, Lawrence HB, Martin MB, Patricia C, Mary D, Julian ED, Mark WJF. Gray's Anatomy. 38th Edition. Philadelphia: Churchill Livingstone, 1995, pp-1538.
2. Huber GC. Pierrsol's human anatomy in the vascular system. 9th Edition. Philadelphia: J.P Lippincott Williams and Wilkins Co, 1930, vol.1, pp-767-791.
3. Patnaik VVG, Kalsey G, Singla Rajan K. Trifurcation of brachial artery- A case report. JASI. 2001; 50 (2):163-165.
4. Bilodi AK, Sanikop MB. Variation in termination of brachial artery- A case report. KUMJ 2004; 2(1): 49-51.
5. Nakatani T, Tanaka S, Mizukami S. Superficial ulnar artery originating from the brachial artery and its clinical important. Surg Radiol Anat 1998; 20(5):383-5.
6. Cuneyt B, Enis U, Tunc K. A case of originated high superficial ulnar artery. Trakia Journal of Sciences. 2004;2(3): 70-73.
7. Bhat KM, Potu BK, Gowda S. High origin of ulnar artery in south indian male cadaver: a case report. Rom J Morphol Embryol 2008; 49(4):573-575.
8. Rodriguez-Niedenfuhr M, Burton GJ, Den J, Sanudo JR. Development of the arterial pattern in the upper limb of staged human embryos: normal development and anatomic variations. J Anat 2001; 199(4):407-417.
9. Baeza AR, Nebot J, Ferreira B, et al. An anatomical study and ontogenic explanation of 23 cases with variations in the main pattern of the human brachio-antebrachial arteries. J Anat 1995; 187(Pt 2):437-39.
10. Singer E. Embryological pattern persisting in the arteries of the arm. Anat Rec 1933; 55:403-409.