

Case Report

Challenges of Physiotherapy Management: Type 4 Knee Arthrofibrosis Following Traumatic Multiple Structural injuries of Knee in a 16-year Old Boy: A Clinical Case Report

Vijayakumar P, Leonard HJ, Ayiesah HR

Physiotherapy Programme, School of Rehabilitation, Faculty of Health Sciences, Universiti Kebangsaan Malaysia, Jalan Raja Muda Abdul Aziz, 50300, Kuala Lumpur

Abstract

Traumatic knee crush injuries of degloving nature carries a greater risk for the multitude of complications rendering emergency surgical intervention the treatment of choice in the majority of such injuries. These types of injuries commonly result in a unique post-operative complication such as arthrofibrosis and it presents overly challenge for Physiotherapists managing it. In this retrospective single-case report, we describe the challenges of in – and out-patient physiotherapy treatment planning for a 16-year old boy throughout the continuum of care for his knee arthrofibrosis following a series of surgical procedures. As result of his complex medical situation, the time-specific physiotherapy intervention during the immediate post-operative period failed to improve our patient's knee function. The knee function with regard to range of motion (especially extension), muscle strength(quadiceps) improved considerably with the adoption of an aggressive physiotherapy intervention approach that included specific quadiceps muscle strengthening, joint mobilization (rotation/traction) in sitting position with legs over the edge of table and contract-relax quadiceps stretching in prone position using theraband.

Keywords: Salter-Harris type IV, arthrofibrosis, knee injuries/surgery, physiotherapy rehabilitation, case report

Correspondence:

Vijayakumar Palaniswamy, Lecturer, Physiotherapy Programme, Faculty of Allied Health Sciences, Universiti Kebangsaan Malaysia, Jalan Raja Muda Abdul Aziz, 50300, Kuala Lumpur, Malaysia. Tel: +603-2687 8003, Fax: +603-2687 8199 Email: physiovjy@yahoo.com

Date of submission: Dec 22,2011

Date of acceptance: March 15, 2012

Introduction

According to the Salter-Harris paediatric fracture classification, type IV Salter-Harris fractures usually involves the epiphysis plate, metaphysis and epiphysis. As these types of fractures involve the epiphysis, the growing layer of articular cartilage can be damaged, which can lead to possible growth retardation. Greater risk of complications arises from fracture of the distal tibia and followed by the distal femur (1) A high incidence of ligament laxity has been related with the occurrence of physeal injuries about the knee (2).

Loss of knee range of motion after any severe injury or surgery is well accepted event and the condition which typifies this process is described as arthrofibrosis (3). According to Shelburne et al classification of arthrofibrosis, type 4 arthrofibrosis patients have an extension loss of $>10^{\circ}$ and total flexion of $<120^{\circ}$ with patellar tightness (4). Pain, stiffness (worse in the morning), loss of motion, swelling, crepitation, and quadiceps weakness were few common clinical manifestations reported by authors of the published articles (5). It is reported that this condition possibly will occur as the consequence

of the inflammatory cascade due to injury or operative treatment. Arthrofibrosis pathophysiology studies have shown that adhesive bands, Cyclops lesion, patella infera syndrome, malpositioned graft that impinges in the notch leading to knee range of motion limitation(5).

Surgical treatment of knee arthrofibrosis is commonly performed if there is a limitation of knee flexion to less than 75° and if left untreated, the progressing knee arthrofibrosis can cause impairment in daily activities (6). This case report presents the rehabilitation challenges that were experienced during the management of type 4 arthrofibrosis associated with Salter-Harris Type IV fracture and degloving, multiple structural injuries to knee in a 16-year-old boy.

Case Report

A 16-year-old boy ambulating with crutches, on admission to our out-patient Physiotherapy Department presented with a painful, stiff and swollen right knee. Retrospective review and analysis of medical records indicated the following.

In January 2011, the boy suffered a severe road accident when a truck's rear wheel ran over the right side knee after knocking down his two wheeler. Emergency room medical screening showed a complex compound fracture dislocation and degloved injury to his right knee (Fig. 1). Computed tomographic arthrography (CTA) reports confirmed posterolateral dislocation of tibia and fibula: fractures of right tibial plateau, patella and comminuted fractures of the lateral femoral condyle with chondral damage to the medial tibia. Ultrasound reports indicated tendinopathy of right side patella tendon (thickness 0.6cm), torn popliteus, anterior and posterior cruciate ligaments ACL & PCL) with medial collateral ligament (MCL) intact. Vascular assessment performed prior to emergency procedures showed an absence of peripheral pulses of right lower limb.

Two days following injury, the patient required a sequence of operating procedures, which included wound debridement, manipulation, and placement of two cannulated screws transversely across the femur distal to the growth plate and finally stabilization of fracture segments with Pre-Fix temporary external fixator (TEF) at 30 degree flexion of the knee. In addition the boy had follow – up surgical procedures, including revision of screw fixation with epiphysiodesis of medial femoral condyles, repair of the torn medial patello-femoral ligament. (MPFL) were performed three-week post initial injury.

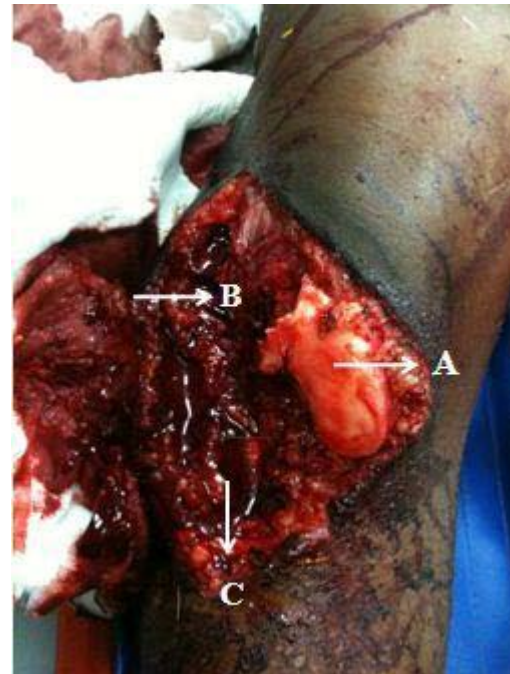


Figure 1: Showed the right knee open fracture dislocation. A- Patella fracture B-Degloving skin' C-Tibial fracture

Initial in-patient physiotherapy:

The in-patient physiotherapy regimen immediately after the surgery was limited to short arc quadriceps exercises, straight leg raises and circulatory exercises to non-affected side. The patient required moderate assistance required for wheel chair ambulation. The patient was then discharged with a temporary external fixator in place.

On readmission after 6 months, the boy presented with increased knee stiffness (Arthrofibrosis), muscle weakness and decreased daily activities as a main complaint. Pre-operative physiotherapy assessment revealed decreased knee range of motion (flexion = 60°, extension = -15°), soft tissue swelling, and hypertrophic scarring over the right knee. In addition, laboratory examination included erythrocyte sedimentation rate (62mm/hr.), and C-reactive protein level (0.80mg/dl) Based on aspiration culture and laboratory data, right knee was determined to be free of infection.

In Aug 2011, the boy had a diagnostic arthroscopic evaluation of the knee which shown a type 4 arthrofibrosis with abundant fibrotic tissues covered all over the joint, extensor mechanism, intercondylar notch, patella femoral joint and also intra-articular bone fragment from previous fracture reported. Subsequently, manipulation under anaesthesia (MUA),

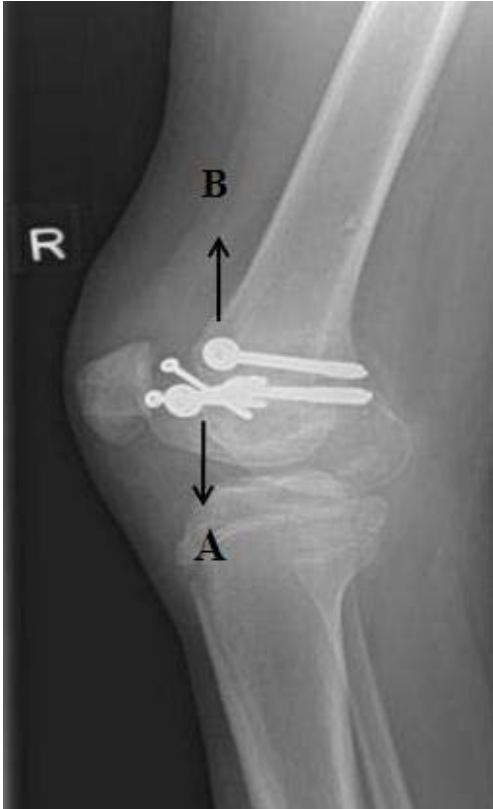

Figure 2: Radiograph of Right Knee Shows Cannulated screw fixation for femoral condylar fracture. A-Condylar fracture, B- Cannulated screws

arthroscopic knee release (lateral) with removal of screws performed and immediately after the procedure, Continuous passive motion (CPM) device set for motion from 0-45 degrees was recommended. One week after the procedure the boy was then allowed for ambulation with crutches with instructions to maintain non-weight bearing status. Outpatient physiotherapy was prescribed to manage the arthrofibrosis conservatively. Post-operative physiotherapy assessment findings following arthroscopic knee release and MUA indicated mild effusion, moderate pain, and consistent knee joint range of motion limitation with significant quadriceps muscle weakness, ligamentous instability, medial side (knee) numbness and thick scar running over the anterior aspect of the right-side knee (Table 1).

One week after the procedure the boy developed haemarthrosis on the right knee which further complicated and delayed his outpatient rehabilitation. Following eight days after the arthroscopic release, the right knee was aspirated under local anaesthesia.

Knee aspiration revealed a right knee synovial haemoserous fluid and portal wound at the anterior

medial site. The patient was then again referred for physiotherapy to manage arthrofibrosis on an outpatient basis. Almost nine months since the initial knee injury, the boy still presented with inferior gains in knee function, in spite of getting several surgical procedures (MUA, Arthroscopic release).

On the other hand, early phase of rehabilitation (in-patient physiotherapy) was constantly interrupted and delayed due to the frequent revision of operative procedures and their subsequent complications. Weight bearing on the right knee was not recommended until the confirmation of fracture healing which posed a risk for further knee stiffness and muscle weakness. Moreover, the in-patient time-specific treatment goals were not met as the patient had frequent immobilization following the surgical procedures including the MUA.

Outpatient Physiotherapy:

At this phase of rehabilitation, an aggressive treatment strategy with physiotherapy sessions on a daily basis was adopted; which seemed to produce a slightly higher gain in knee range of motion (right knee flexion = 125°, extension = 0°) (Table 1) and quadriceps muscle strength. We initiated a knee strengthening program with moderate to high intensity of exercises for quadriceps to increase extension using galvanic muscle stimulation and followed by joint mobilization (rotation/traction) in sitting position with legs over the edge of table and contract-relax quadriceps stretching in prone position using theraband. Two physiotherapists were involved in the joint-mobilization techniques. The boy was positioned prone on the table with having one therapist to provide longitudinal traction along tibia and the other therapist to provide anterior and posterior glides to improve range of motion. Aquatic therapy exercises like walking and knee ROM exercise at chest level water was recommended three times a week in addition to home exercise program emphasising quadriceps strengthening using theraband.

Full weight bearing on the right knee was initiated after ultrasound scan confirmation of complete fracture healing. The boy appeared to have better response to this aggressive physiotherapy approach than the earlier “watch and wait” approach during immediate post-operative period. Subsequent progressive strengthening exercises and gait training was possible with newly gained knee range of motion and muscle strength (4/5 MMT overall) (Table 1). He could participate in functional training without experiencing knee pain, effusion and discomfort with activities. The boy was

Table 1: Findings of physiotherapy evaluation performed at post-operative arthroscopic release and discharge with home exercise program (HEP*)

Time line	Physiotherapy Evaluation
Arthroscopic Lateral Release with manipulation under Anaesthesia PO*.	<p>General Observation: Ambulation with crutches, Left side pelvic shift Partial weight bearing Swollen right knee.Hypertrophy scar over right knee.</p> <p>Objective Examination: Pain: VAS* 4/10 on weight bearing and 6/10 on walking (toe touch).</p> <p>Joint effusion :</p> <p>Range of Motion:</p> <p>Knee flexion = 70° (right), hard end feel & WNL* (left),</p> <p>Knee extension = -10° (right) & WNL(left)</p> <p>Circumference (midpatellar) : 45cpom(Right) & 41cm(left)</p> <p>Ankle : WNL</p> <p>Manual Muscle strength (MMT) : hip flexion with SLR(right)- unable to perform,</p> <p>Hamstring 3/5 right & 4/5 left</p> <p>Quadriceps 3/5 & 4/5 left</p> <p>Ankle PF & DF = WNL(bilateral)</p> <p>Standing Balance: fair (static) & poor (dynamic) (Berg Balance scale)</p>
Discharge with HEP*	<p>Objective Examination:</p> <p>Range of Motion</p> <p>Knee flexion : 125° Knee extension = 0</p> <p>Muscle strength:</p> <p>Hamstring 4+/5 Quadriceps 5/5 (right side)</p> <p>Hamstring & Quadriceps 5/5 (left side)</p> <p>Balance : fair static and dynamic balance</p>

WNL* -within normal limits
 VAS*- visual analog scale
 PO* - postoperatively

then discharged with HEP X daily with instruction to continue the strengthening and range of motion exercises. Upon physical therapy examination on discharge, knee flexion and extension was measured as 125°- 0 respectively (Table 1).

Discussion

This case report described the physiotherapy management of Type 4 arthrofibrosis following a traumatic multiple structural knee injury and for which the boy underwent a series of surgeries and including MUA as a salvage procedure. The patient gained a reasonable extent of recovery from arthrofibrosis with fair gains in terms of knee range of motion and muscle strength.

Following the review of literature it appeared that the so called standard treatment care for arthrofibrotic knee with contrasting rates of success included closed manipulation, arthroscopic debridement, open procedures including revision surgery and physiotherapy (5). In addition CPM and physiotherapy approach were considered as the adjunctive therapy of arthrofibrosis (7). However the current research literature provides ill-defined rehabilitation programs or guidelines for physiotherapist treating arthrofibrosis. Most published articles recommend manual and exercise therapy as the mainstay physiotherapy intervention without describing the specific ways to achieve the treatment goals (8).

Moreover, the authors of a published article even suggested that MUA with arthrolysis as the treatment of choice, if the initial physical therapy or non-operative methods for arthrofibrosis is not successful or if the loss of motion develops after 3 months (9). In this patient, the right side knee range of motion was neither improving nor plateau with any of the revision surgery or MUA. In addition, the in-patient “wait-and-watch” physiotherapy treatment approach toward arthrofibrosis failed to restore the knee function and delayed the progression. Varatharaj et al implied that insufficient rehabilitation in the postoperative period because of psychogenic or other reasons may have important bearing on the post-surgical knee outcomes. (10). our outpatient physiotherapy treatment strategy focussed on gaining the range of motion and quadriceps muscle strength (quadriceps strength is priority) as early as possible by adopting an aggressive and holistic physiotherapy intervention. The authors believe that the addition of ambulation and knee range of motion exercises under water aquatic therapy exercises might further enhanced the healing and recovery from arthrofibrosis. Aquatic exercises are considered safe and effective exercises after the surgical incisions is completely healed and moreover water based exercises allows appropriate joint loading and reduce unwanted stresses on the healing structures (11).

Conclusion

Prevention is the paramount therapy for managing arthrofibrosis but most of the current physiotherapy interventions like CPM, quadriceps strengthening exercises, electrical stimulation, ultrasound, patellar mobilization, friction massage and other adjunct programs such as aquatic therapy were attempted in many of the previous published articles. However, clinical Physiotherapists need systemic and specific treatment protocols for managing severe form of arthrofibrosis like grade III and above. Furthermore, there is a serious lack of level 1 evidence or studies to support the efficacy of specific physiotherapy interventions for arthrofibrosis. This case report might provide a framework to future prospective and randomized controlled trials on determining the specific physiotherapy protocols for arthrofibrosis.

References

1. Cass JR, Peterson HA. Salter-Harris Type IV injuries of distal tibial epiphyseal growth plate with emphasis on those involving medial malleolus. *Bone Joint Surg Am* 1983; 65(8):1059-1070.

2. Brone LA, Wroble RR. Salter-Harris Type III fracture of the medial femoral condyle associated with an anterior cruciate ligament tear. *Am J Sports Med* 1998; 26(4):581–6.
3. Millett PJ, Williams RJ 3rd, Wickiewicz TL. Open debridement and soft tissue- release as a salvage procedure for the severely arthrofibrotic knee. *Am J Sports Med* 1999; 27(5):552–561.
4. Shelbourne KD, Patel DV, Martini DJ. Classification and management of arthrofibrosis of the knee after anterior cruciate ligament reconstruction. *Am J Sports Med* 1996; 24(6):857–862.
5. Fitzsimmons SE, Vazquez EA, Bronson MJ. How to treat the stiff total knee arthroplasty? : A systematic review. *Clin Orthop Relat Res* 2010; 468(4):1096-1106.
6. Hutchinson JR, Parish EN, Cross MJ. Results of open arthrolysis for the treatment of stiffness after total knee replacement. *J Bone Joint Surg Br* 2005; 87(10):1357-1360.
7. Millett PJ, Johnson B, Carlson J, Krishnan S, Steadman JR. Rehabilitation of the arthrofibrotic knee. *Am J Orthop(Belle Mead NJ)* 2003; 32(11):531–8.
8. Biggs A, Shelbourne KD. Use of knee extension device during rehabilitation of a patient with type 3 arthrofibrosis after ACL reconstruction. *N Am J Sports Phys Ther* 2006; 1(13):124–131.
9. Creighton RA, Bach BR. Arthrofibrosis: Evaluation, Prevention, and Treatment, *Techniques in Knee Surgery* 2005; 4(3):163-172.
10. Mounasamy V, Beizile E, Moskal J, Brown T. Stiffness following total knee arthroplasty: evaluation and treatment. *European Journal of Orthopaedic Surgery & Traumatology* 2008, 18:165-171.
11. Garrison JC, Osler MT, Singleton SB. Rehabilitation after arthroscopy of an acetabular labral tear. *N Am J Sports Phys Ther* 2007; 2 (4):241-50