

Technical report

CT-Guidance Combined with Fluoroscopy for Tunnelled Translumbar Catheterization of Inferior Vena Cava: A Technical Case Report

Nik Rizal NY¹, Shahrina MH¹, Abdullah M², Rozman Z², Sobri M² (✉)

¹Department of Diagnostic Imaging, Hospital Selayang, Selayang, Selangor

²Department of Radiology, Universiti Kebangsaan Malaysia Medical Centre, Jalan Yaacob Latif, Bandar Tun Razak, 56000 Cheras, Kuala Lumpur, Malaysia

Abstract

Patients with end-stage renal disease typically require catheter hemodialysis during the time required for fistula or graft maturation or after other methods of hemodialysis are exhausted. When patients requiring indwelling catheters develop central venous occlusions, unconventional routes to the central veins are used. Translumbar catheterization of inferior vena cava is considered as one of the options for central venous access. We highlight a case of Translumbar central venous tunnelled catheterization performed under Computed Tomography (CT) guidance combined with fluoroscopy in a 40-year-old lady with end-stage renal failure.

Keywords: CT-Guidance, translumbar, central venous catheter, hemodialysis

Correspondence:

Dr. A. Sobri Muda, Associate Professor, Department of Radiology, Universiti Kebangsaan Malaysia Medical Centre, Jalan Yaacob Latif, Bandar Tun Razak 56000 Cheras, Kuala Lumpur, Malaysia.

Fax: +60391737824.

Tel: +603-9145 6172

Email: sobri_muda@yahoo.com

Date of submission: 24 Jan 2011

Date of acceptance: 17 Mar 2011

Date of publication: 6 Apr 2011

Introduction

The traditional access for a central venous catheter is through the subclavian or internal jugular vein. However, in patients with central vein obstruction, alternative routes are needed such as the inferior vena cava (IVC), for placement of the catheters. Translumbar placement of IVC catheters is performed only in patients considered to have few or no other options and is not intended as the primary central venous access.

There are different routes to gain access to the IVC, routinely transfemoral and rarely translumbar or transhepatic. The translumbar catheterization of IVC been used for chemotherapy, antibiotics, plasmapheresis, hemodialysis, parenteral nutrition or others (1). The translumbar catheterization of IVC is generally performed under fluoroscopic guidance rather than Computed Tomography (CT) combined with fluoroscopy guidance. CT guidance combined

with fluoroscopy is able to clearly define the anatomy of the IVC and its relationship to the surrounding structures, making the puncture more accurate. We describe translumbar placement of the central venous catheter using CT guidance combined with fluoroscopy.

Case report and technical note.

A 40-year-old lady with Systemic Lupus Erythematosus (SLE)-related end stage renal failure has been on regular haemodialysis for more than 10 years. After all arteriovenous fistulas became non-functional, she relied on central venous dialysis via femoral, jugular, subclavian veins, and peritoneal dialysis. She presented with thrombosed both jugular and femoral veins with peritonitis secondary to peritoneal dialysis.

Prior to the procedure, consent was taken from the patient. Plain baseline CT scan was performed to identify the IVC and to plan the puncture. The access

to the inferior vena cava (IVC) was performed with the patient in prone position under CT guidance. CARE Vision CT 2.4mm-slice with activated HandCARE™ and CARE View™ and zero Gantry Tilt were used for CT guidance (64-slice SOMATOM Sensation, Siemens Medical System). Area of puncture was cleaned and draped. The skin was infiltrated with 5 cc of 2% lignocaine using spinal needle (21G and 15cm length) and intravenous sedation was given (50 mcg fentanyl and 2 mg midazolam) with continuous monitoring of vital signs and oxygen saturation.

Skin puncture was done at the level of L4/L5 and a 22G Chiba needle was advanced and manipulated under CT-fluoroscopic guidance until the tip was seen in the inferior vena cava at the level of L2/L3. To confirm the position, aspiration of venous blood was made with good flow. A 0.018 inch guidewire was advanced through the puncture needle under CT-fluoroscopic guidance. The puncture needle was then removed and the introducer catheter was inserted over the guidewire (AccuStick™ II puncture set; Meditech® - Boston Scientific Corp, the USA). The hub of the introducer was closed with a stopper and secured. The patient was then transferred to the angiographic suite.

On angiography table, in prone position, the patient was again cleaned and draped. Another dose of sedation (IV fentanyl 50 mcg and 1 mg midazolam 1 mg) was given with close monitoring of vital signs and oxygen saturation. Ten ml of 0.5% marcain (bupivacaine with adrenaline 1:200000; Astra-Zeneca) was infiltrated in the subcutaneous tissue for the subcutaneous tract. Three small skin incisions were made. The cuffed dual-lumen catheter 14.5F with 33cm length (Mahurkar™ Maxid™ Tyco Healthcare Group LP, Mansfield, USA) was attached to a tunneler and inserted into the subcutaneous tract and advanced till adjacent to the venous puncture site.

An Amplatz stiff guidewire (0.038 inch) was inserted via an existing introducer, under fluoroscopic guidance and the tip was placed in the superior vena cava. The introducer was then removed and the tract was dilated. Subsequently a 16F valved PULL-APART™ sheath / introducer (Mahurkar™ Maxid™ Tyco Healthcare Group LP, Mansfield, the USA) was inserted over the amplatz guidewire under fluoroscopic guidance. Once it was confirmed in the inferior vena cava, inferior venacavography was performed. The introducer was then removed and bleeding from the sheath was controlled manually. The Amplatz guidewire was inserted into the cuffed dual-lumen catheter and the catheter was slowly inserted via the sheath into the inferior vena cava

under fluoroscopic guidance with the tip placed in the inferior vena cava. The sheath was then peeled apart and removed slowly. Check inferior venacavography was performed to confirm the tip position and flow.

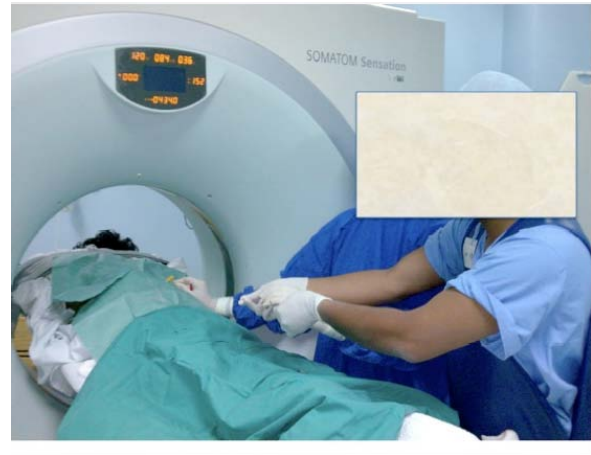

Fig 1: The positioning of patient and puncture of inferior vena cava done under CT guidance.

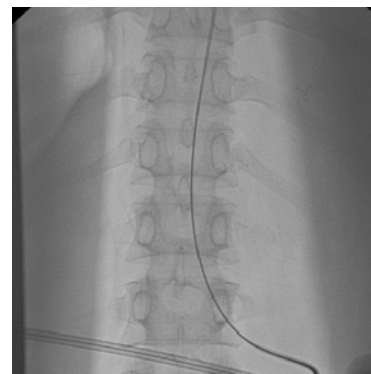


Fig 2: The Amplatz guidewire via the introducer placed in the inferior vena cava and tip of the guidewire manipulated into superior vena cava.

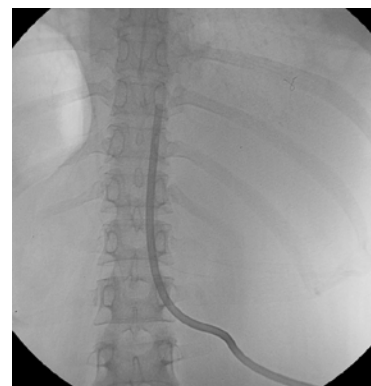

Fig 3: The tip of the dual-lumen catheter placed in the upper inferior vena cava.

Access to the central venous circulation for hemodialysis has traditionally been performed via the

subclavian or jugular venous routes. Different routes have been reported in order to gain access to the IVC which are:- transfemoral, transhepatic and translumbar. Fluoroscopy guidance was the modality of choice for the translumbar placement of the IVC catheter. Translumbar placement of the IVC catheter is an important alternative for central venous access in a patient with difficult venous access. Translumbar placement of IVC catheter was first described by Kenny et al in 1985 (2). Inferior vena caval catheters were placed with a percutaneous translumbar approach to allow central venous access for chemotherapy, harvesting of stem cells, total parenteral nutrition as well as haemodialysis.

Researchers described a safe pathway for percutaneous translumbar IVC cannulation by CT and discussed the slope of the puncture needle under fluoroscopic guidance (3). This suggests that a safe pathway can be determined under CT guidance (3). CT guide also allows clear visualization of various important structures along the puncture tract like the aorta, renal and lumbar arteries and renal veins. This enables the operator to avoid damaging the important structures which is not the case in angiographic fluoroscopic guidance. CT also helps in earlier identification if there is any hematoma.

Mechanical complications of IVC catheters include catheter dislodgment from the IVC, migration into a renal or hepatic vein, and catheter fracture. Other mechanical complications have been described, such as migration or impaction of the tip of the catheter in the renal veins or phrenic veins. This may occur as a result of breathing movement, vomiting, and sudden positional changes of the patient. In most cases the catheter can be repositioned under fluoroscopy with the aid of a guidewire.

The late complications did not differ from those reported when the dialysis catheter is placed in the jugular or subclavian vein (4). However due to high flow within the IVC and the large luminal caliber, thrombosis of the IVC is considered less likely than in femoral and other traditional routes of venous access (5).

Conclusion

CT scan combined with fluoroscopy, provides a simple, safe and practical alternative to conventional fluoroscopic insertion of the dialysis translumbar catheter.

References

1. Lund GB, Lieberman RP, Haire WD, Martin VA, Kessinger A, Armitage JO. Translumbar inferior vena cava catheters for long-term venous access. *Radiology* 1990 Jan; 174(1):31-5.
2. Kenney PR, Dorfman GS, Denny DF Jr. Percutaneous inferior vena cava cannulation for long-term parenteral nutrition. *Surgery* 1985 May; 97(5):602-5.
3. Cazenave FL, Glass-Royal MC, Teitelbaum GP, Zuurbier R, Zeman RK, Silverman PM. CT analysis of a safe approach for translumbar access to the aorta and inferior vena cava. *AJR Am J Roentgenol* 1991 Feb; 156(2):395-396.
4. Smith TP, Ryan JM, Reddan DN. Transhepatic catheter access for hemodialysis. *Radiology* 2004 Jul; 232(1):246-51.
5. Funaki B, Zaleski GX, Leef JA, Lorenz JN, Van Ha T, Rosenblum JD. Radiologic placement of tunneled hemodialysis catheters in occluded neck, chest, or small thyrocervical collateral veins in central venous occlusion. *Radiology* 2001 Feb; 218(2):471-6.